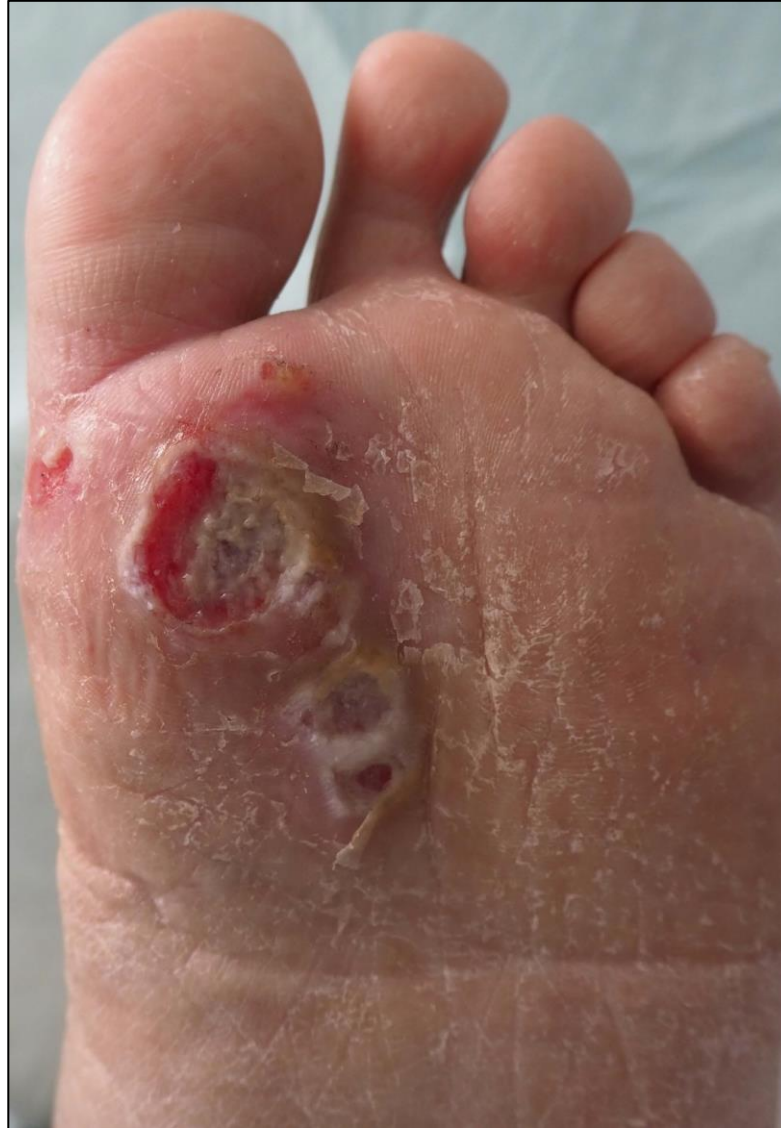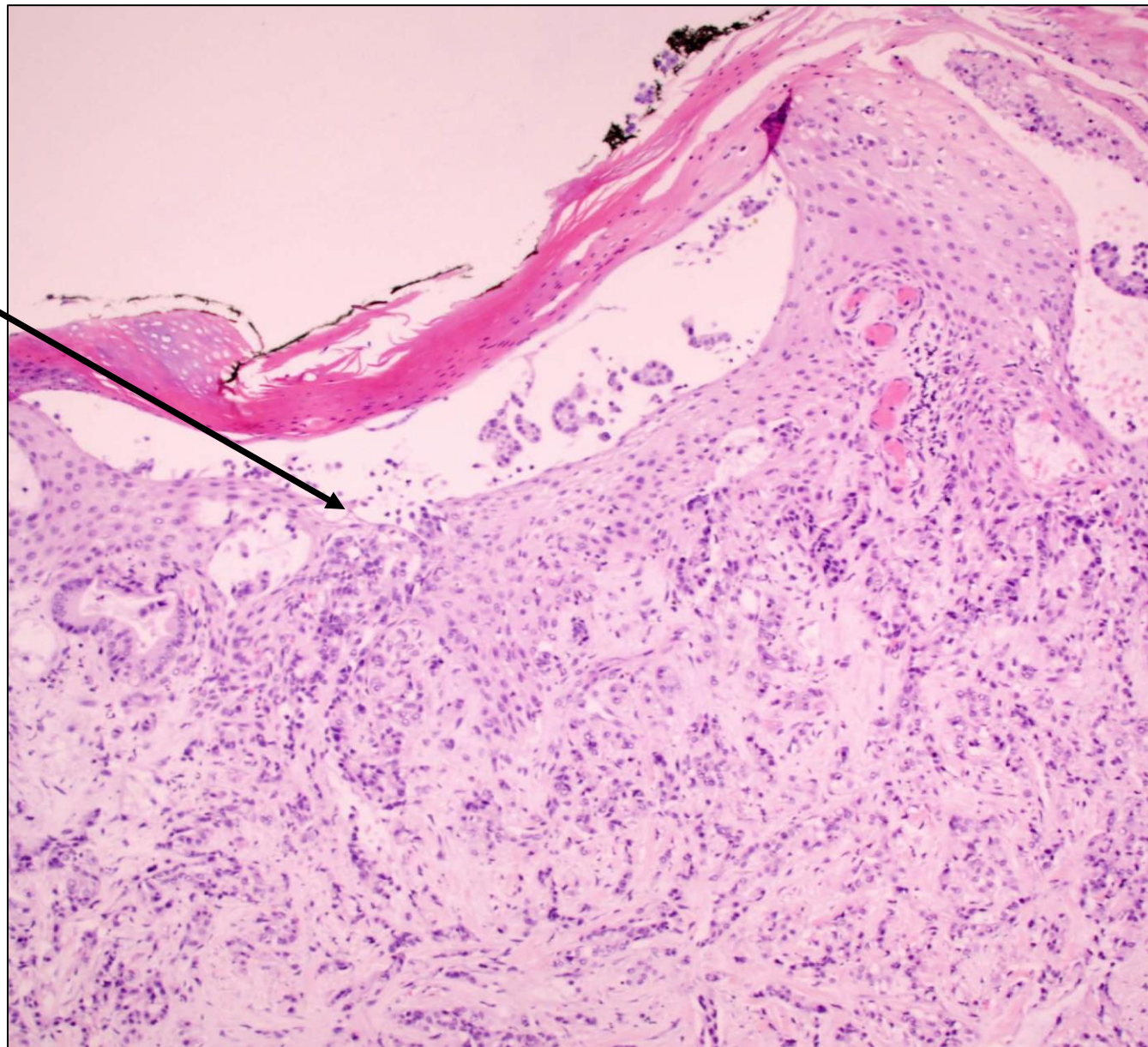


DERMA PEARLS: DERM PATH PEARL - 1

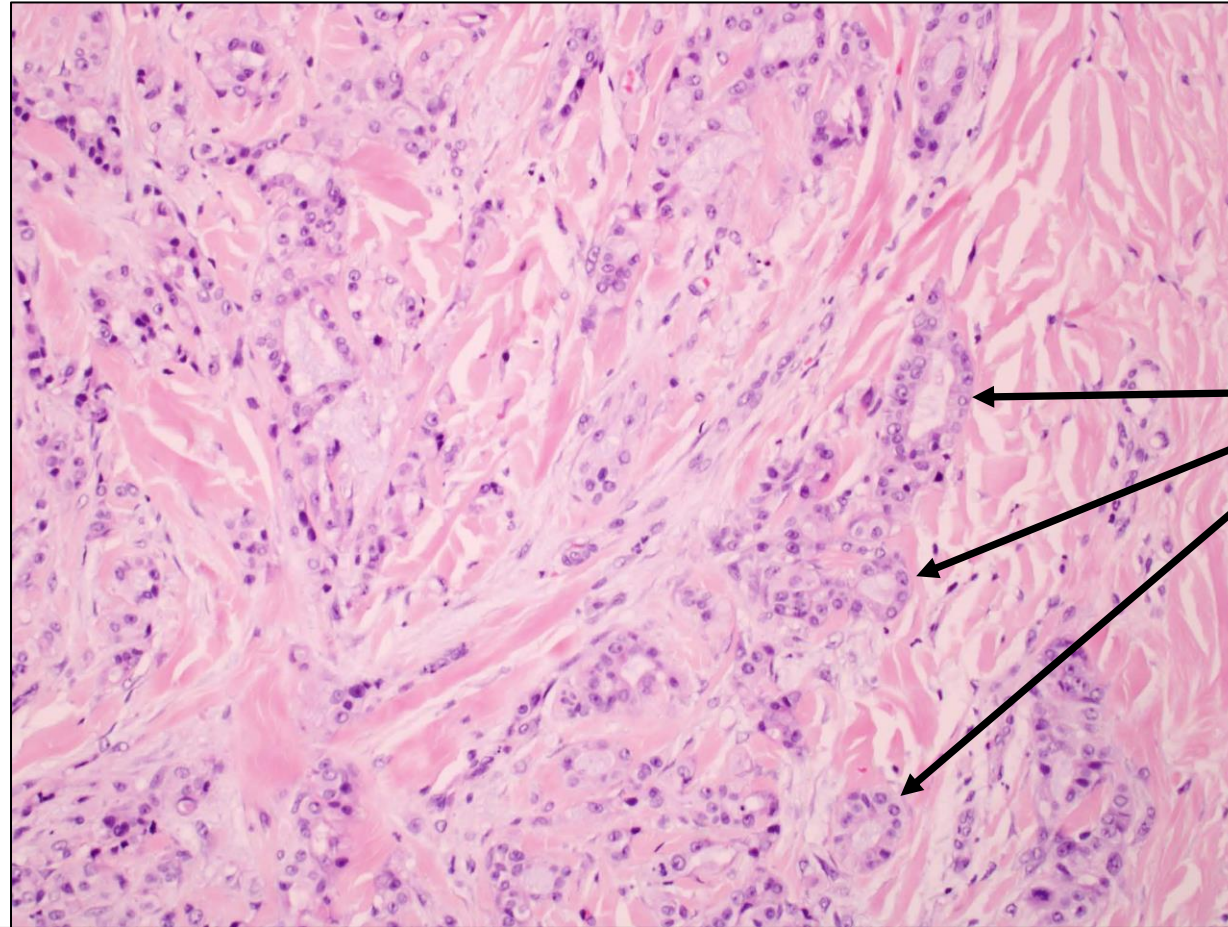


Multiple ulcers and erosions with granulation tissue on the plantar surface of a metatarsophalangeal area of the first toe

Epidermal ulcer



Epidermal ulceration and diffuse infiltration of dermis by tumour cells forming glands (H&E, 10x)



Varying-sized glands

Dermal infiltration by tumour cells arranged in glands (H&E, 40x)

Diagnosis : Cutaneous metastasis from pancreatic cancer misdiagnosed as neuropathic foot ulcer

March-Rodriguez A, Pesqué D, Lobato-Berezo A, Pujol RM. Cutaneous metastasis from pancreatic cancer misdiagnosed as neuropathic foot ulcer. Indian J Dermatol Venereol Leprol 2023;89:883-5.

Compiled by Dr. K. Sudhir babu, MD Path