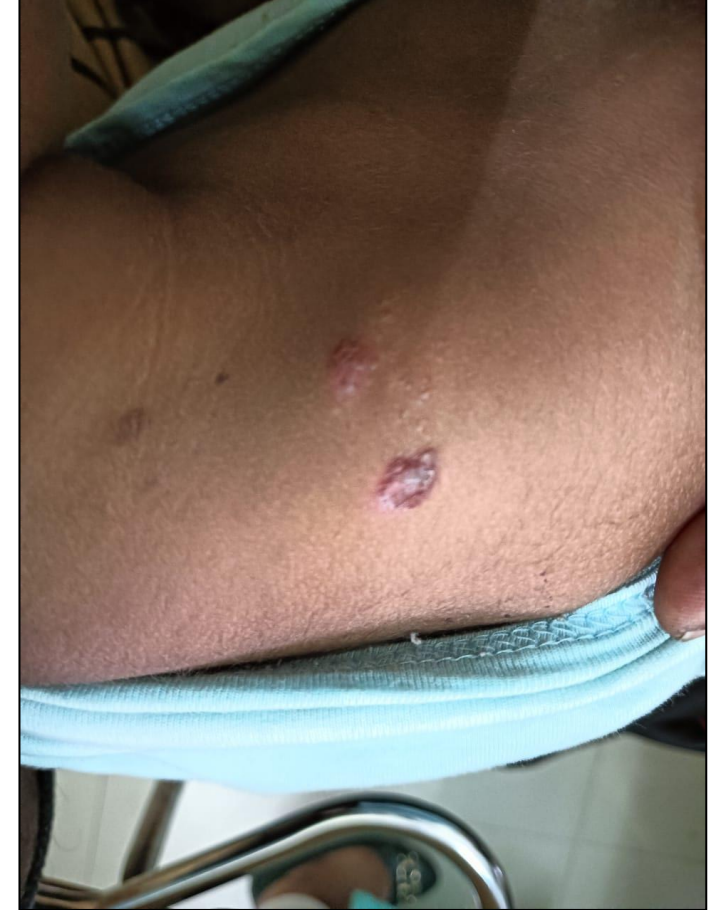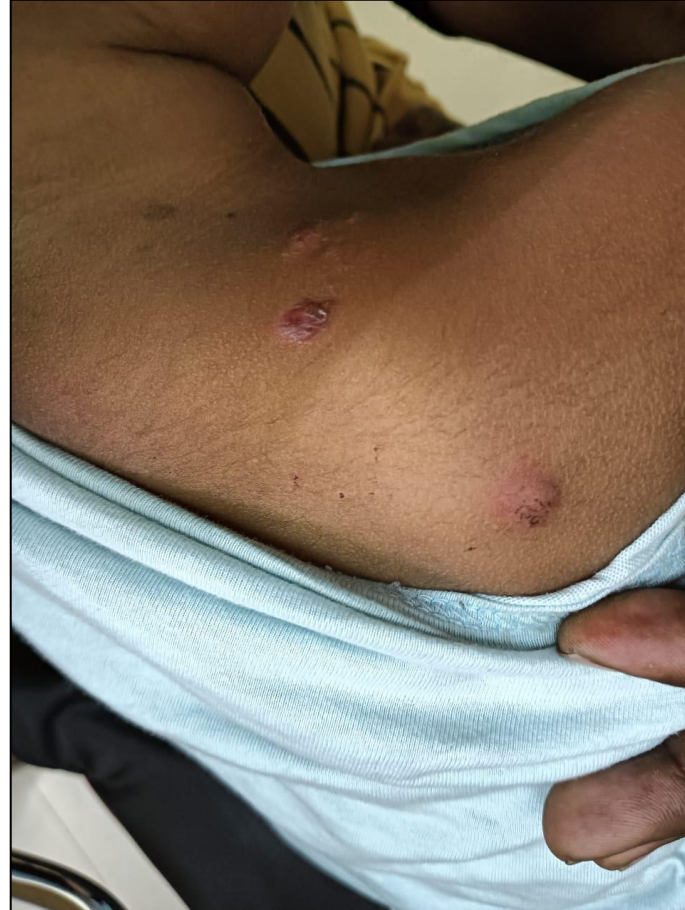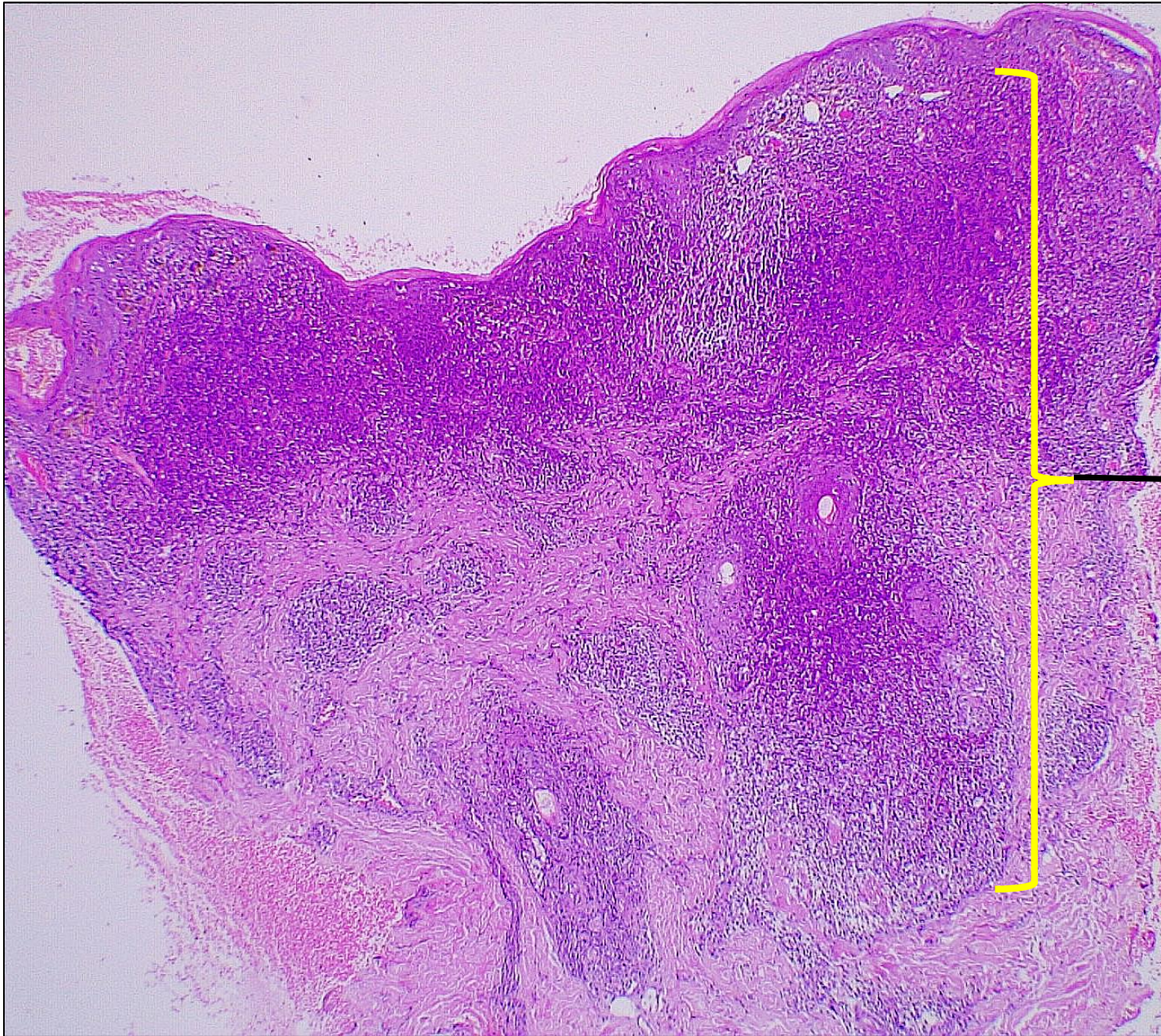


DERMA PEARLS: DERM PATH PEARL - 13

3/Fch;
C/o: Fluid filled lesions over
right shoulder for 1 year;
O/e: Bullous skin lesions with
erythema over the right shoulder



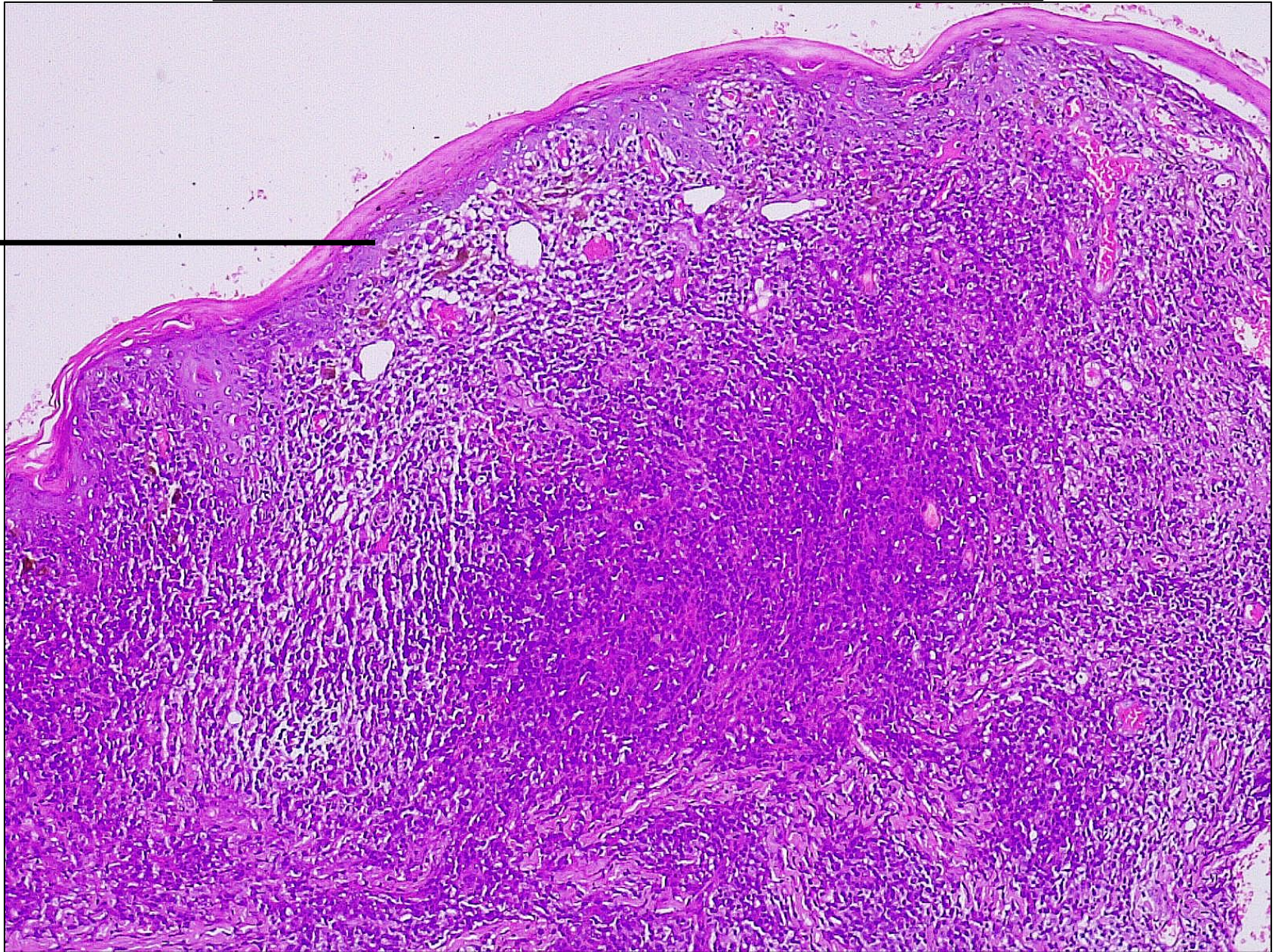
Courtesy: Dr I K V Prasad Lal, Dr Prasad Lal Skin Clinic, Vizianagaram
Dr T Narayana Rao, NR Skin & Cosmetology Centre,
Prof & HOD, GVPIHCMT, Visakhapatnam



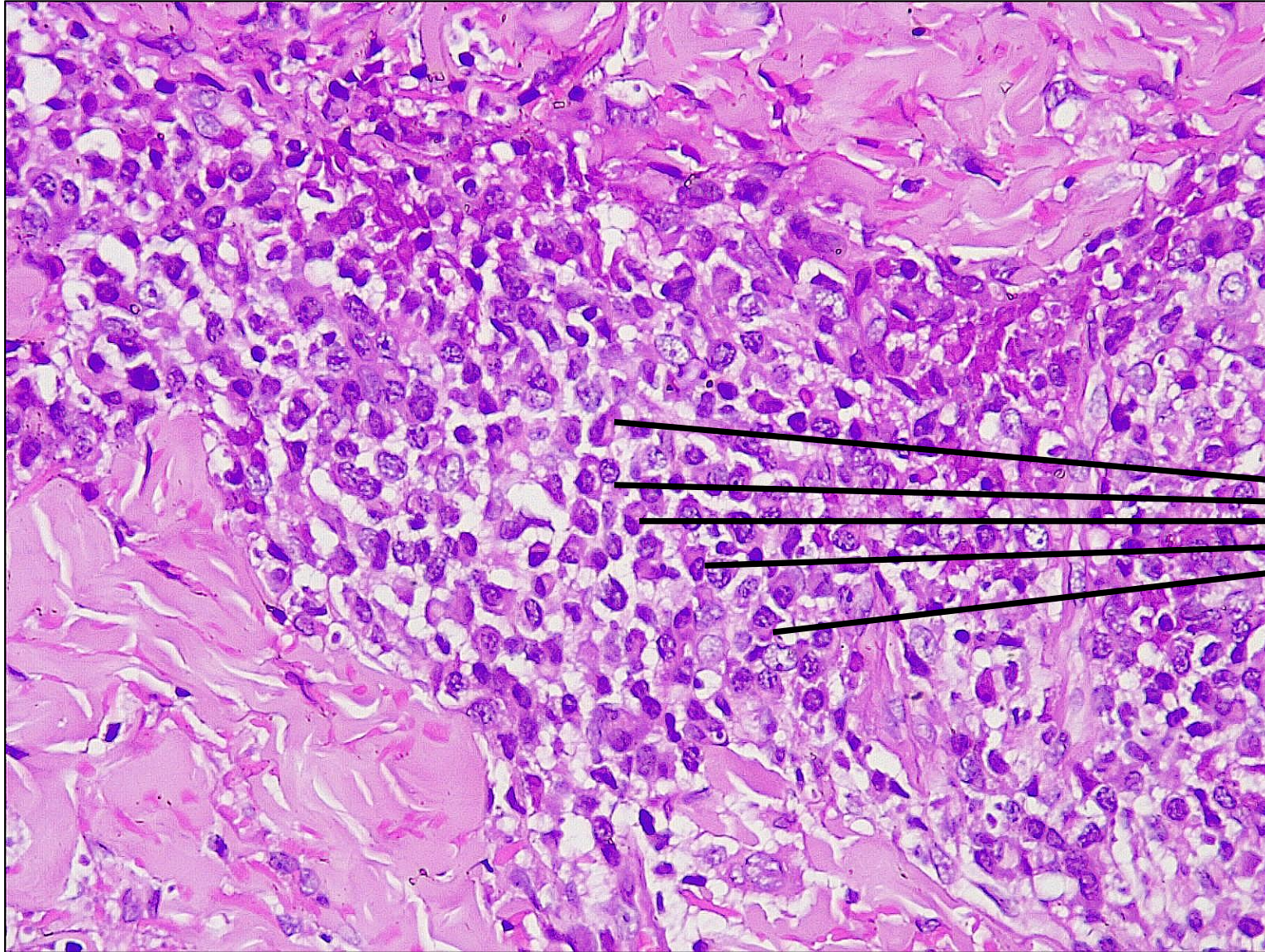
Superficial dermis shows
dense inflammatory infiltrate

Superficial dermis shows dense lymphocytic infiltrate

Thin epidermis



Diagnosis : Cutaneous lymphoid hyperplasia (Pseudolymphoma)



In addition, plasma cells are noted