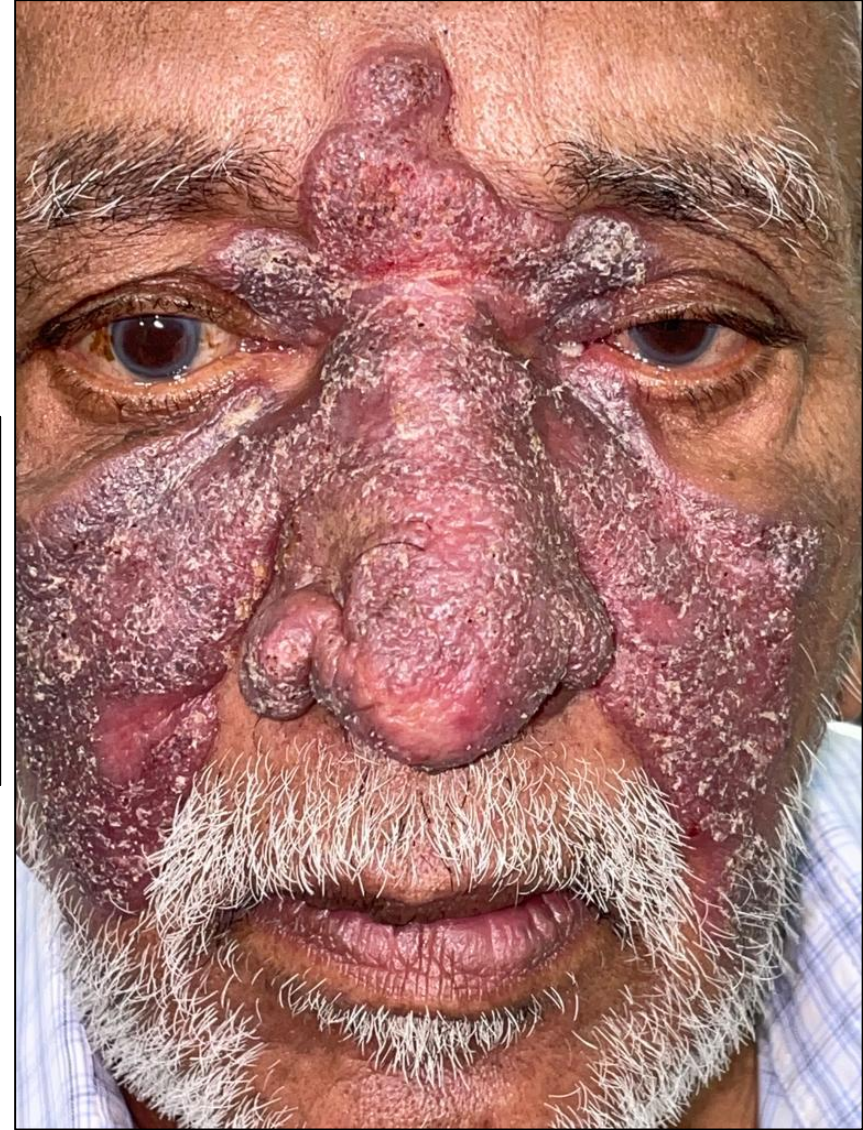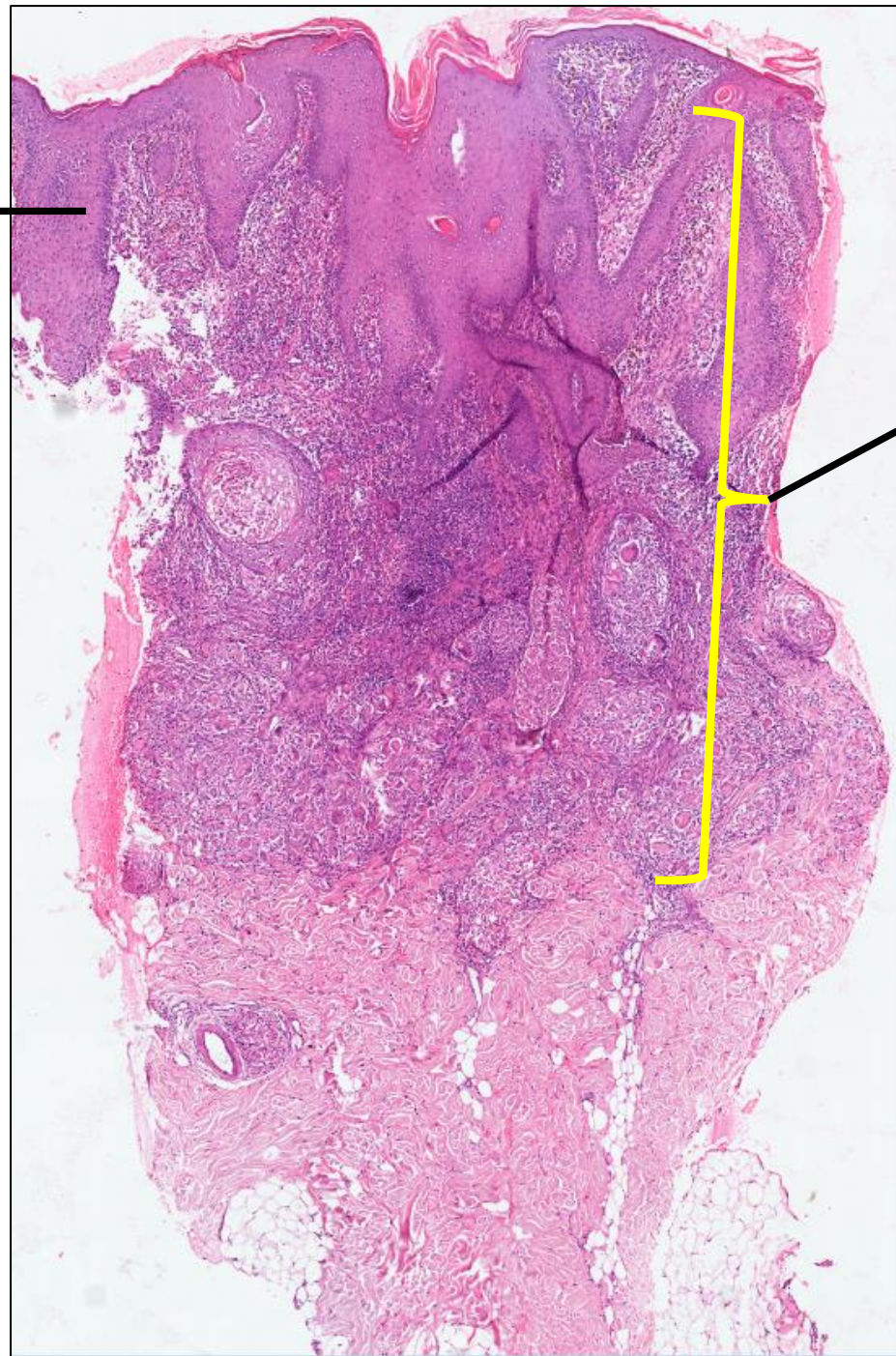


85/M,
C/o red coloured lesions over the face with mild itching
for 2 yrs;
O/e : Erythematous indurated plaque with scaling over
the malar area, extending onto the entire nose, upper
eyelids (medial aspect) and glabella



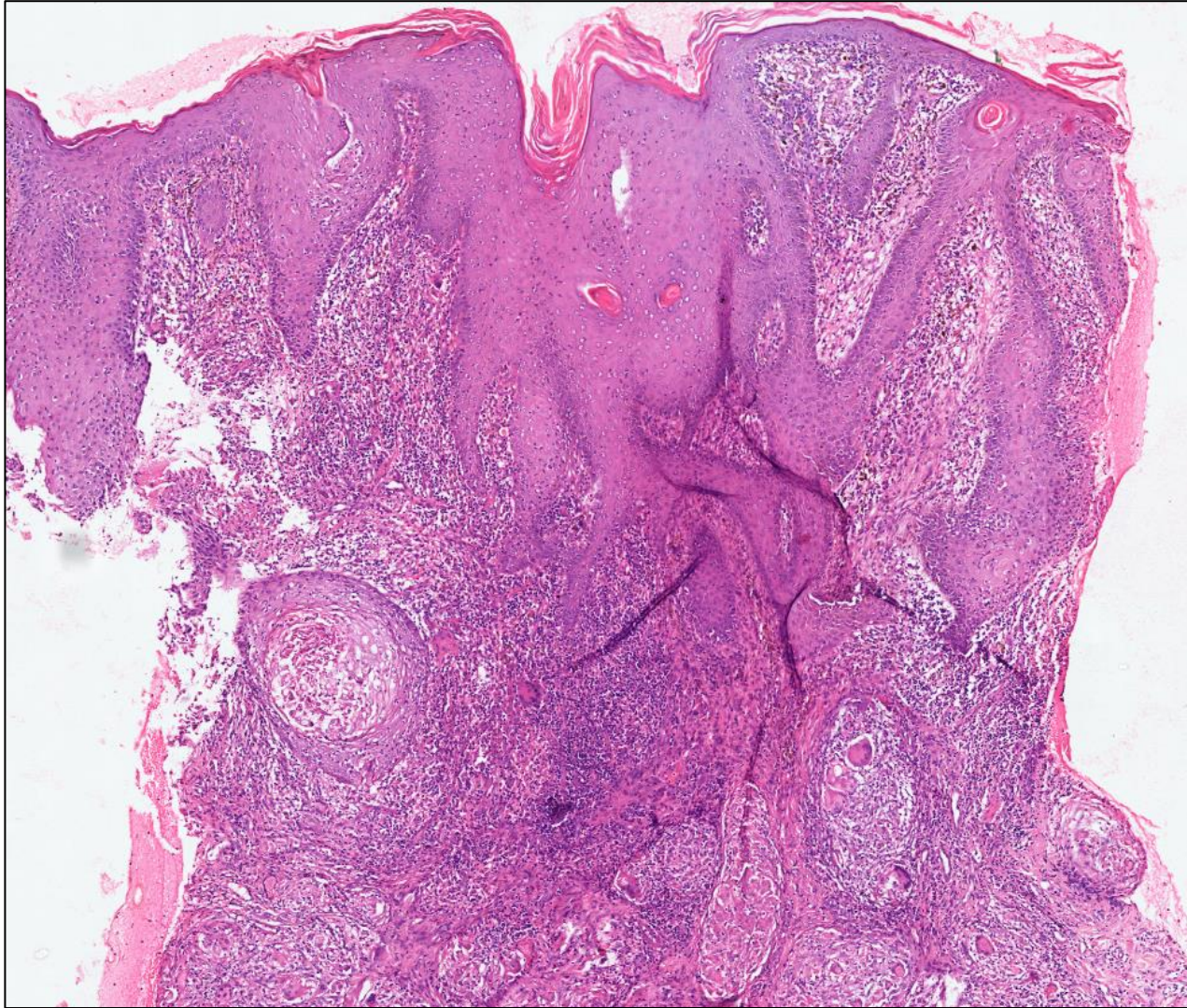Courtesy: Dr T Narayana Rao, NR Skin & Cosmetology Centre,
Prof & HOD, GVPIHCMT, Visakhapatnam

Hyperplastic epidermis :
Marked acanthosis with
irregular elongation of rete
ridges

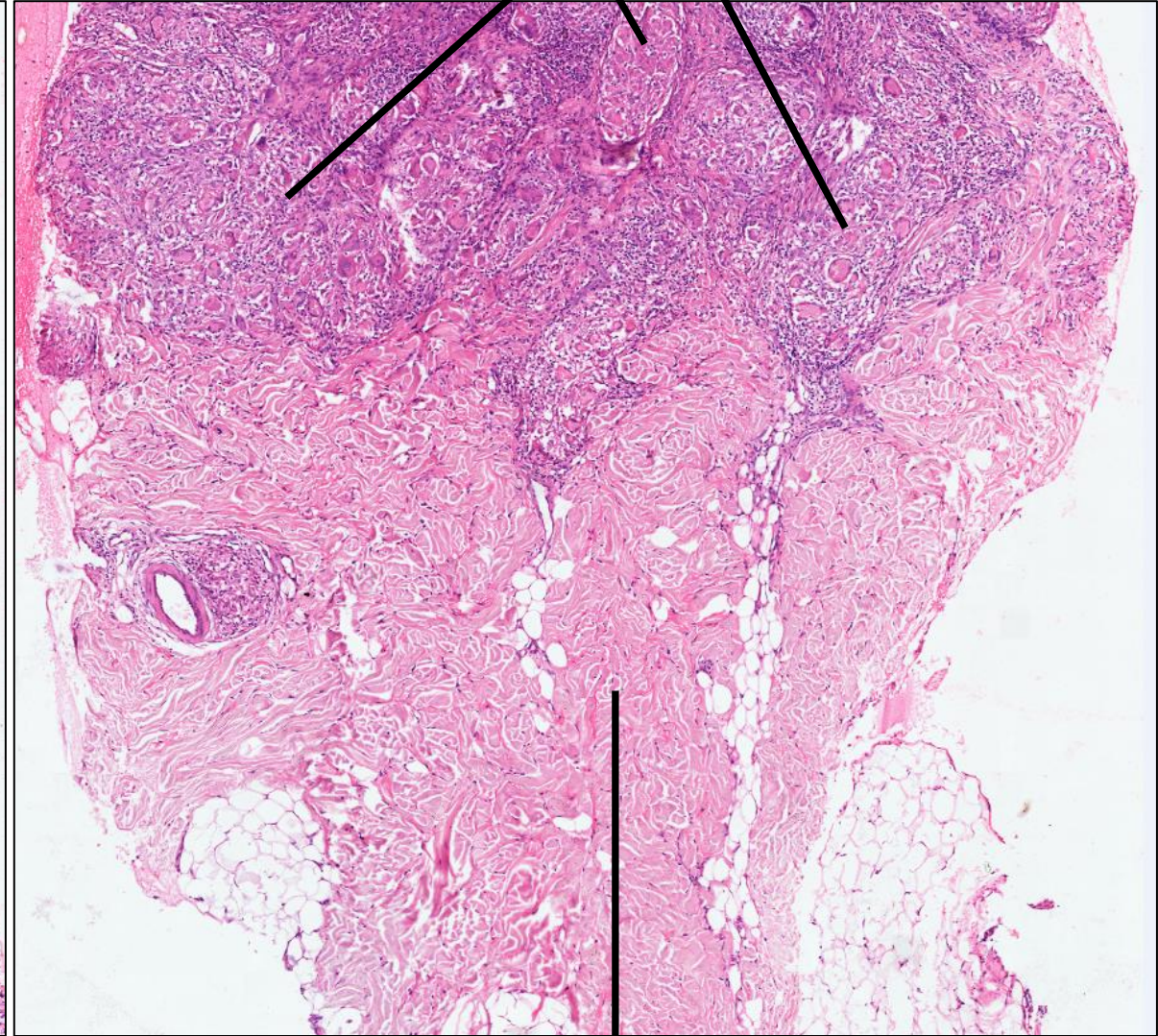


Inflammation is noted mainly
in the superficial dermis

Hyperplastic epidermis

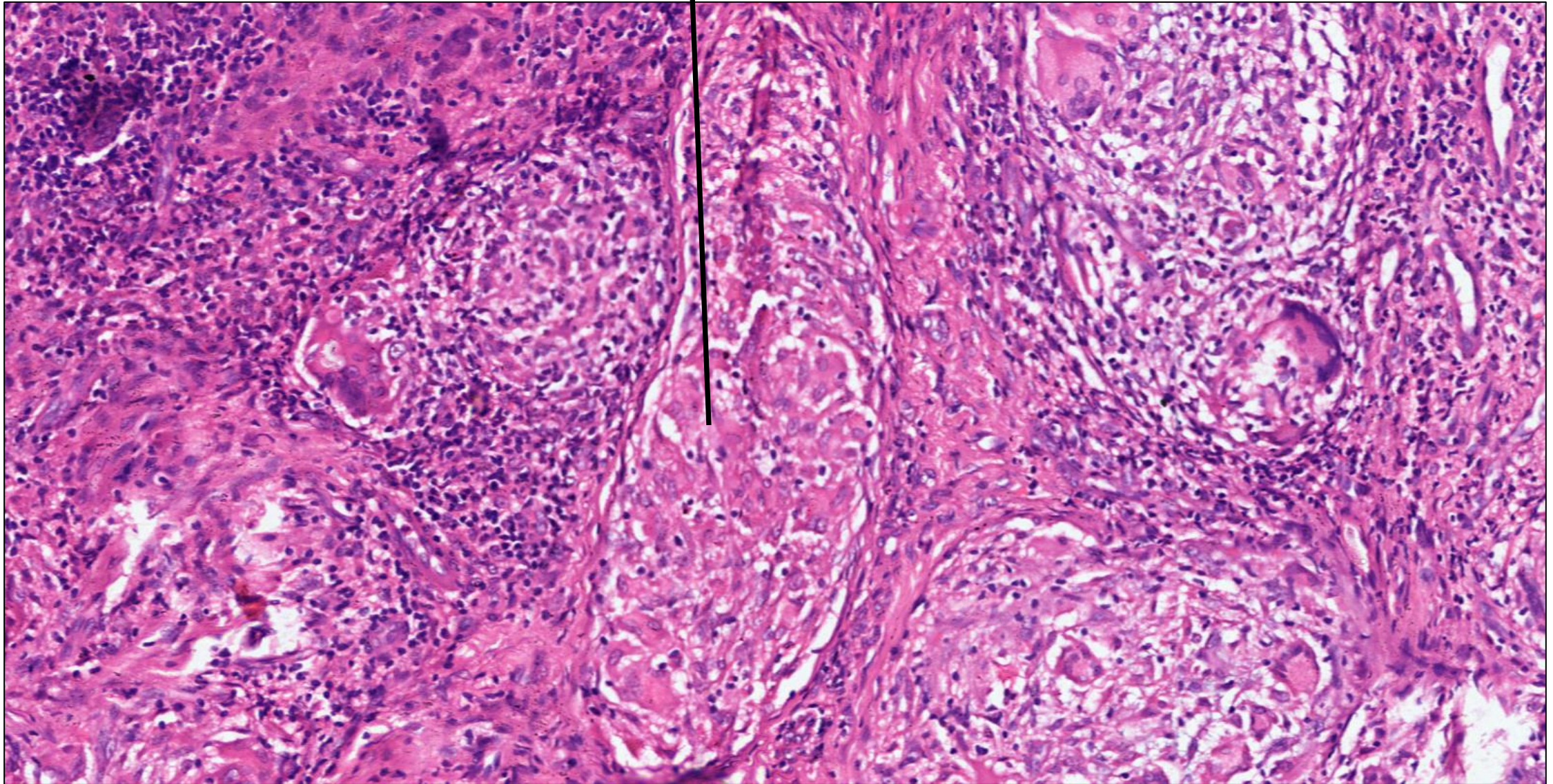


Superficial dermal granulomas

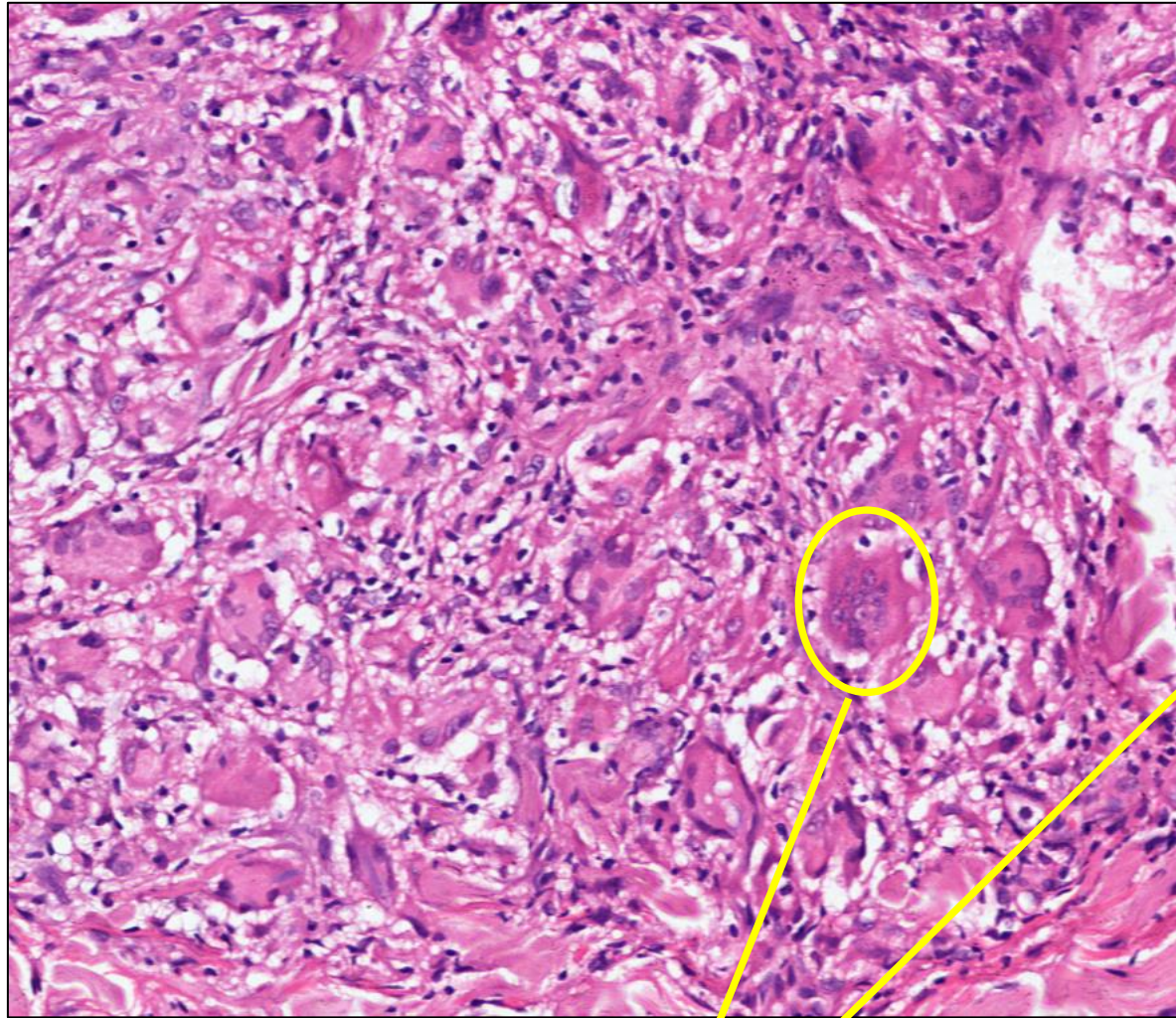


Uninvolved deep dermis

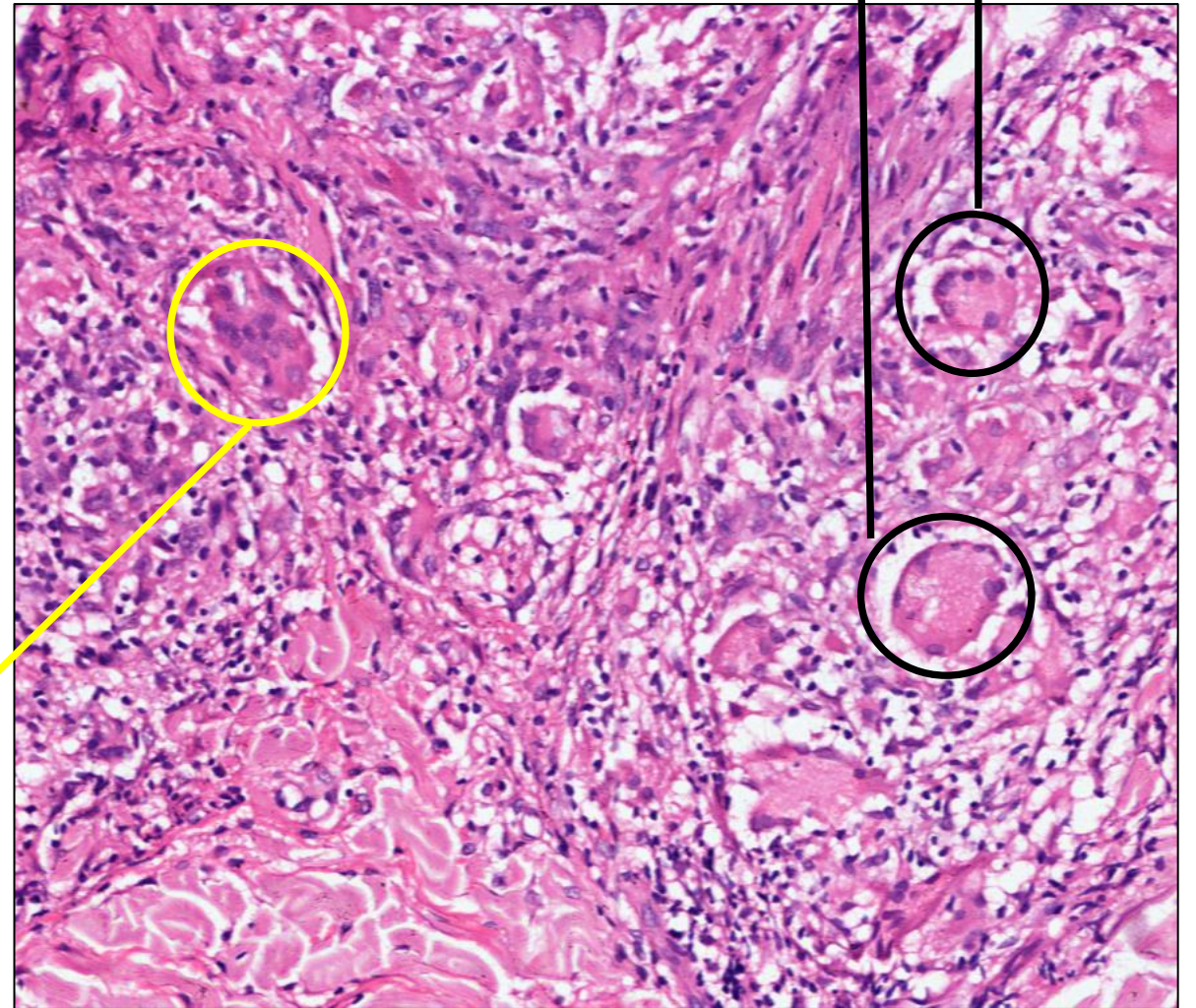
Collection of epithelioid histiocytes (granuloma)



Diagnosis : Lupus vulgaris



Foreign body type of giant cells



Langhan's type of giant cells