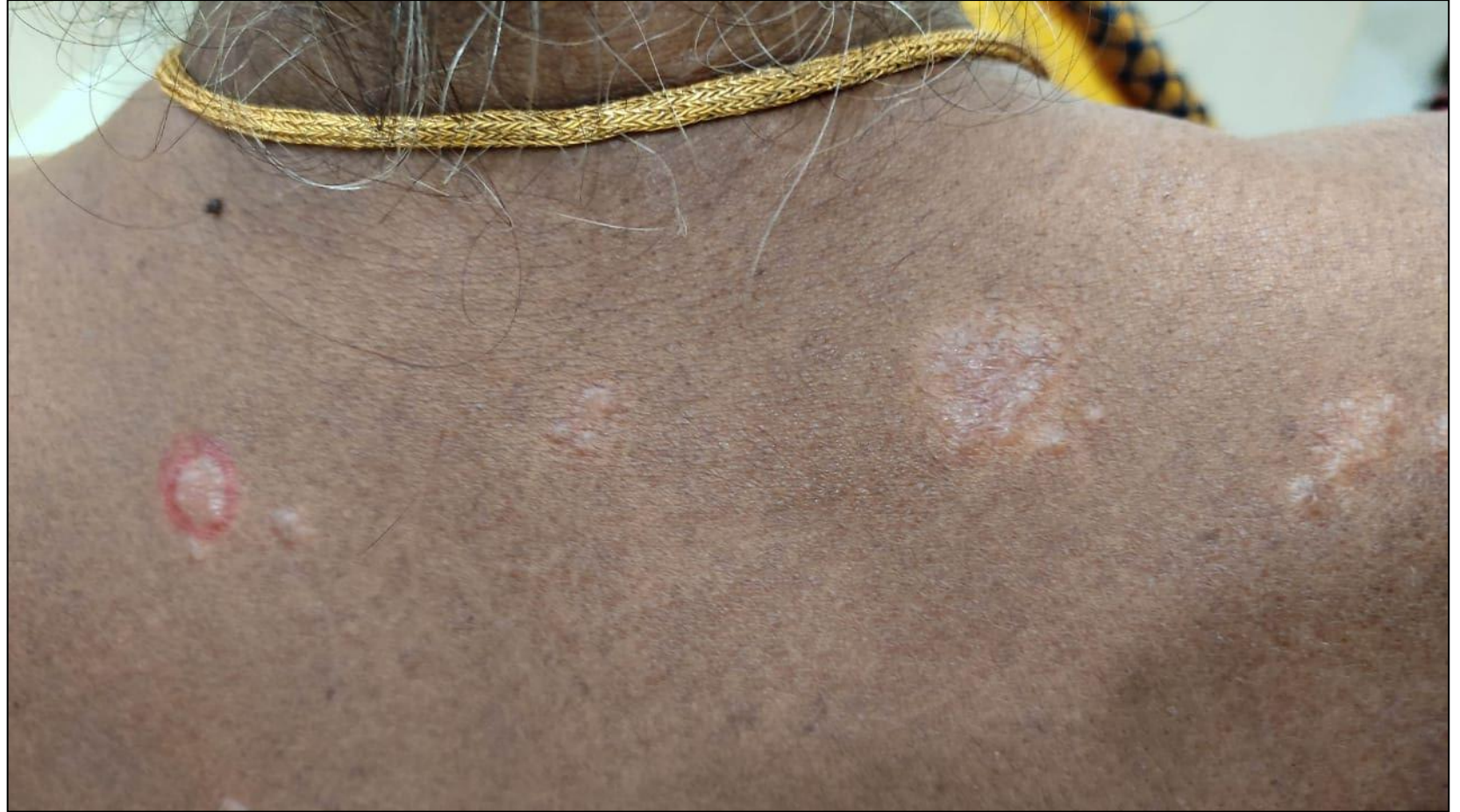

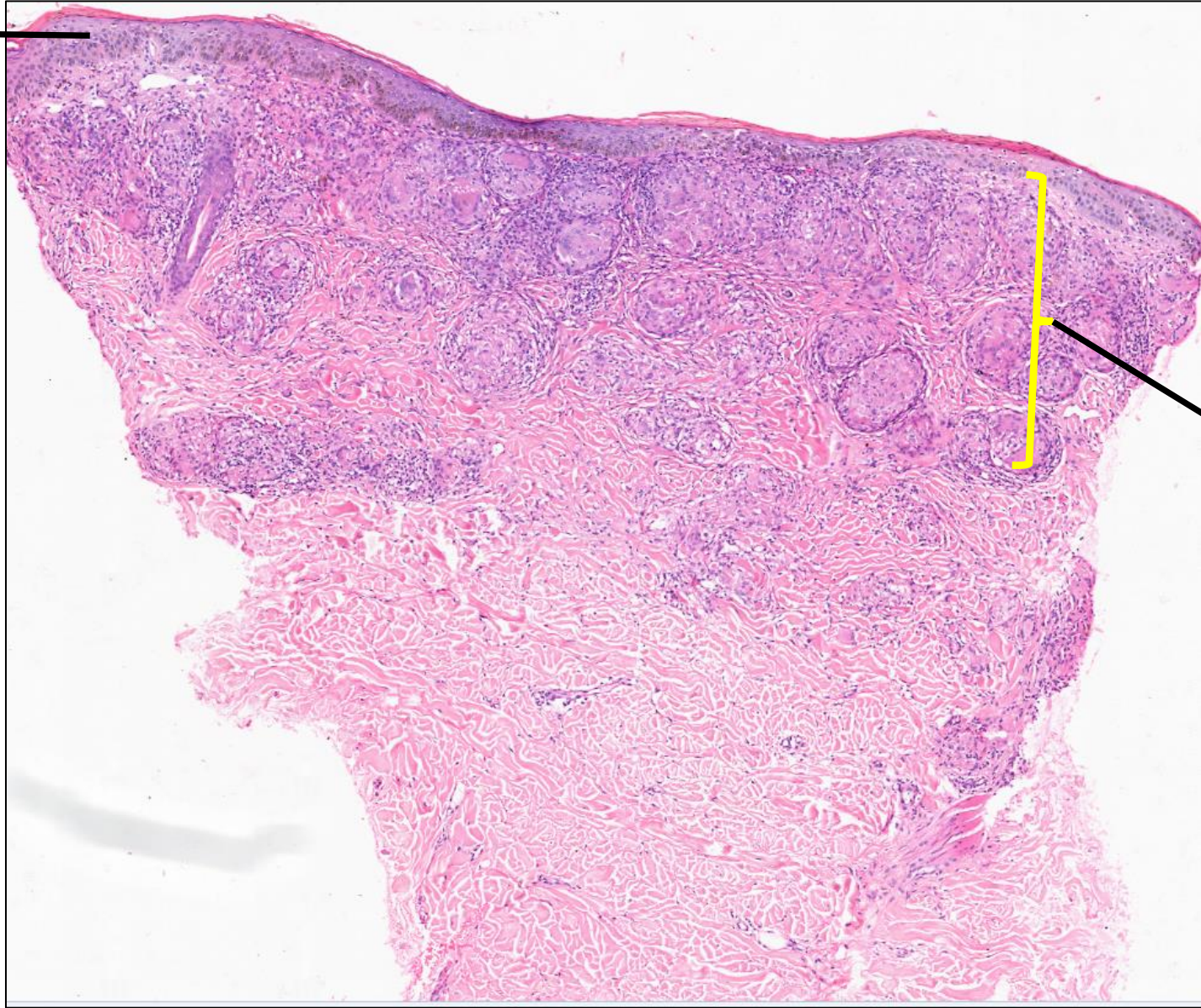
DERMA PEARLS: DERMPATH PEARL - 5

70/F,
O/e : Hypopigmented pruritic
plaques over the upper back for 6
months

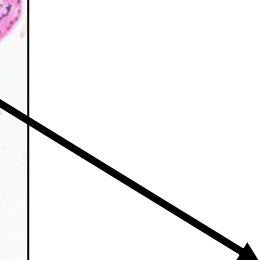


Courtesy: Dr I K V Prasad Lal, Dr Prasad Lal Skin Clinic, Vizianagaram

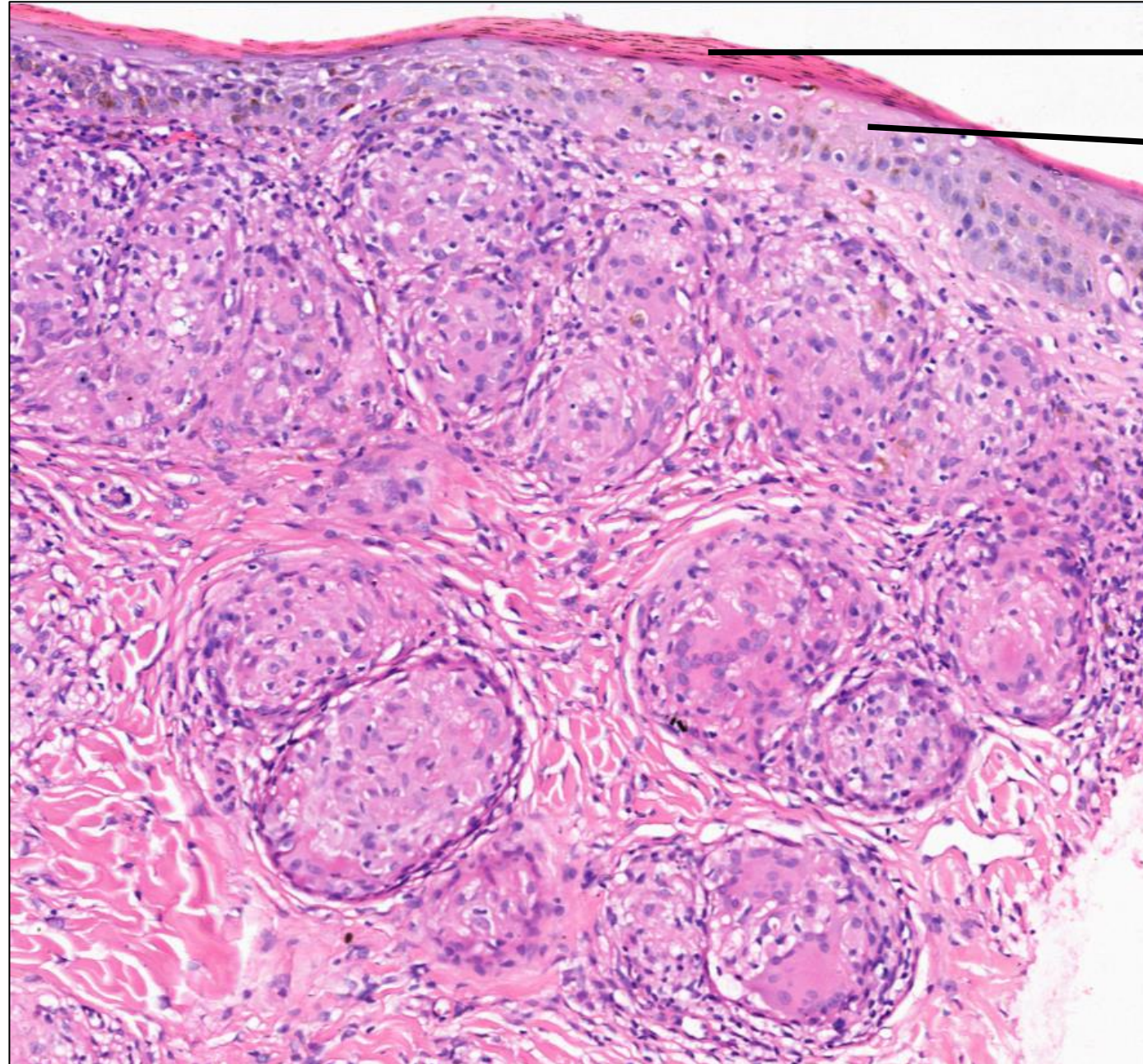
Thin epidermis



Inflammation is noted
mainly in the superficial
dermis



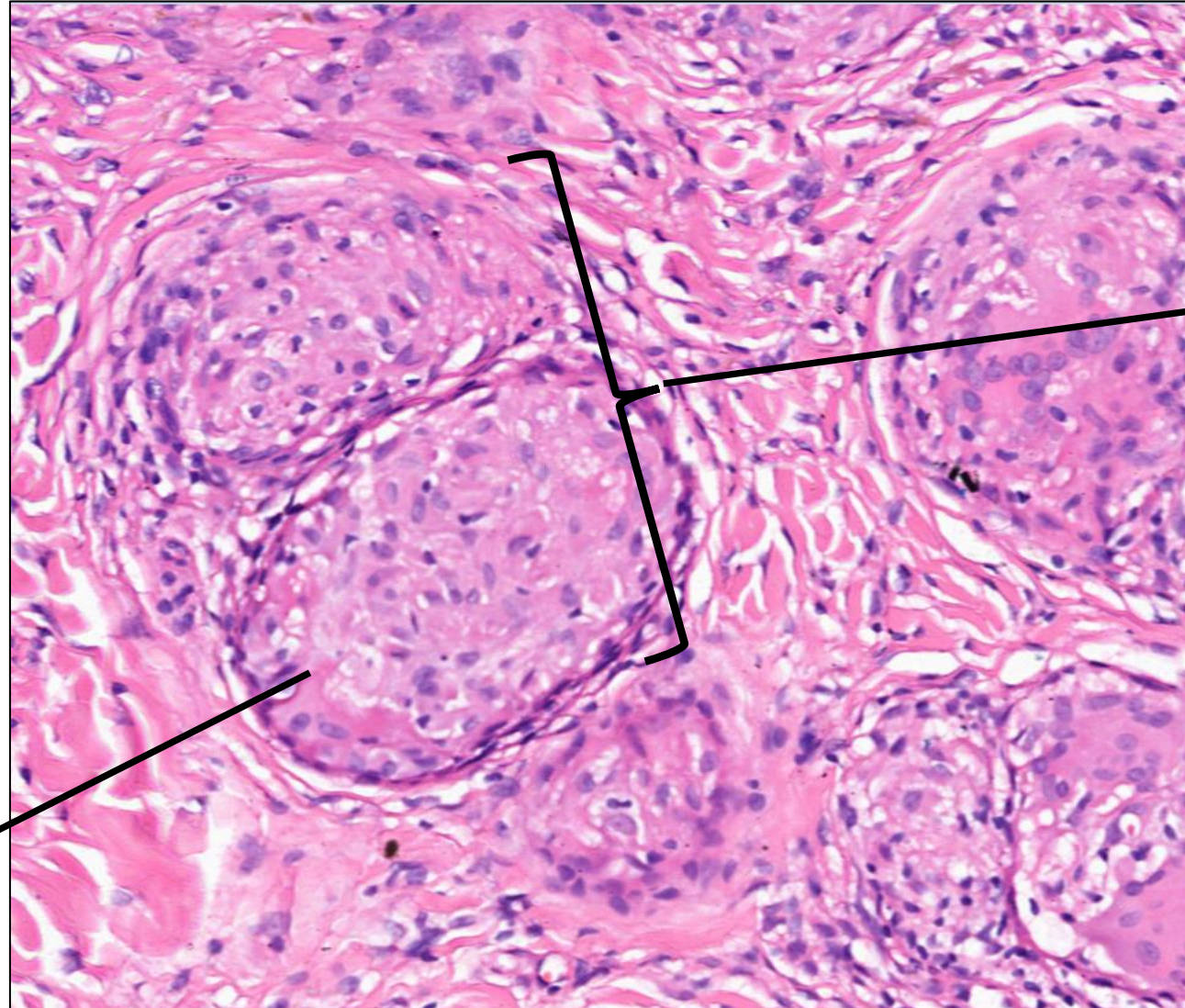
Confluent and naked granulomas in the dermis



→ Parakeratosis

→ Thin spinous layer

Diagnosis : Cutaneous Sarcoidosis



Aggregates of histiocytes
without lymphocytes
(Naked granuloma)

Closely placed granulomas
(Confluent granulomas)