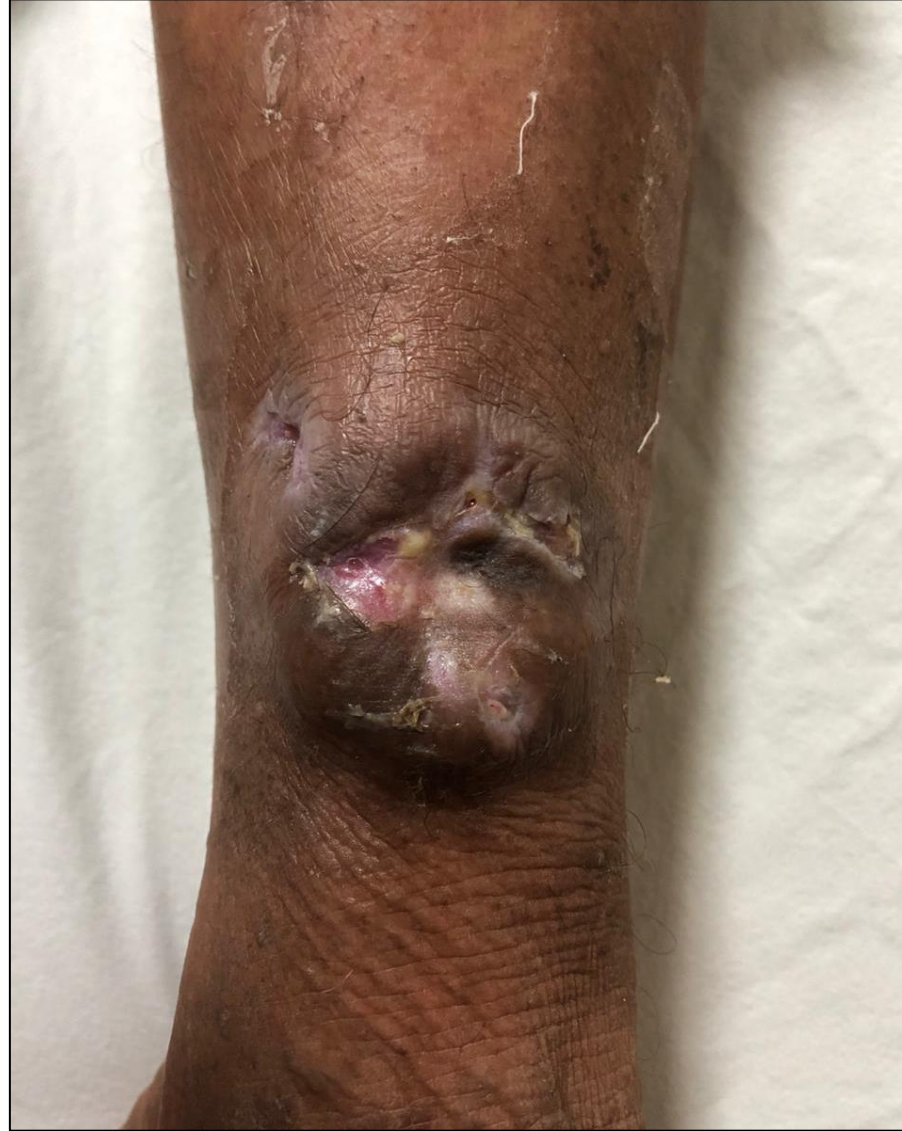

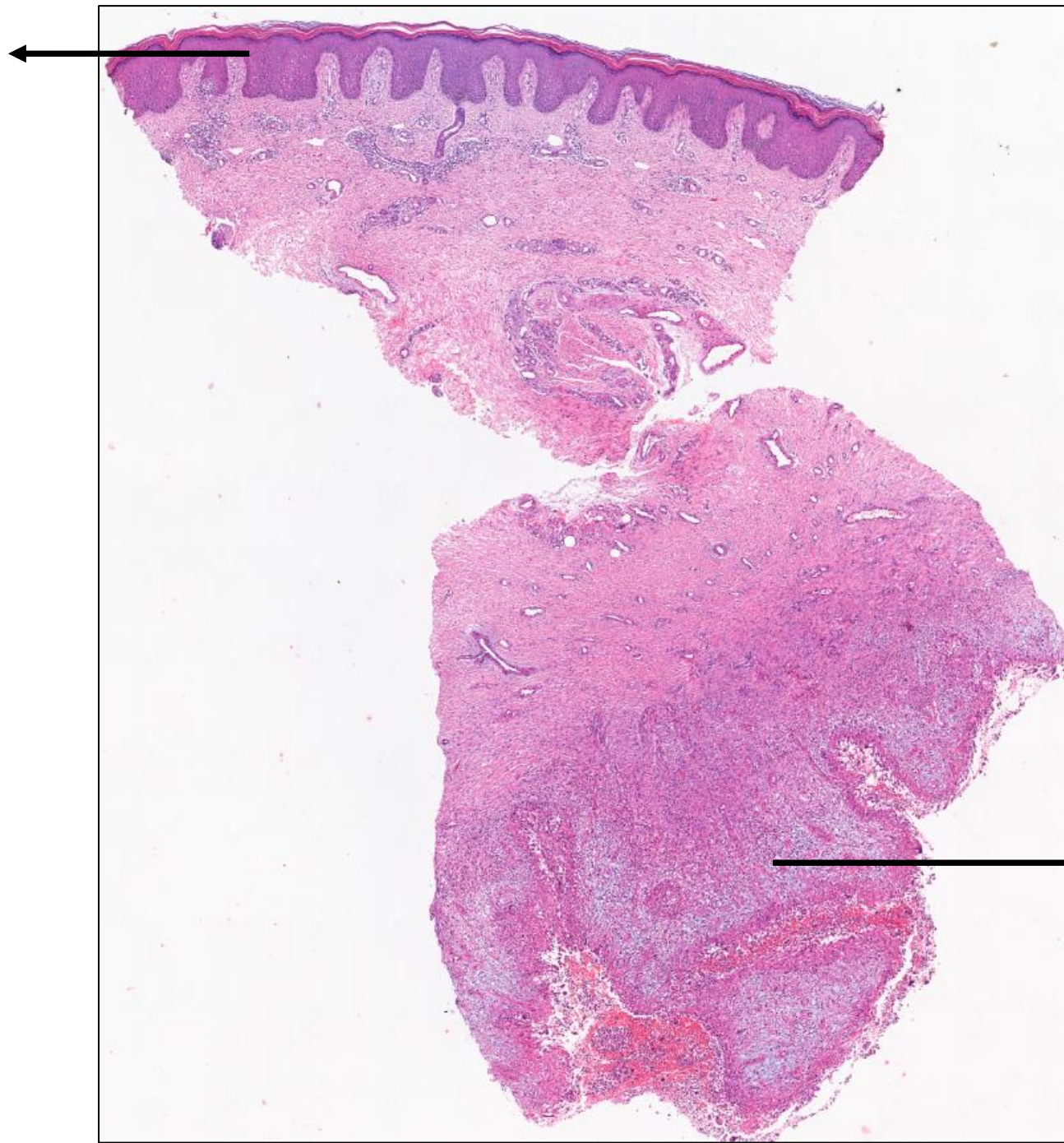
DERMA PEARLS: DERMPATH PEARL - 6

67/M,
Well defined boggy swelling
with induration and sinus tracts;
Over left lower leg for 4 yrs



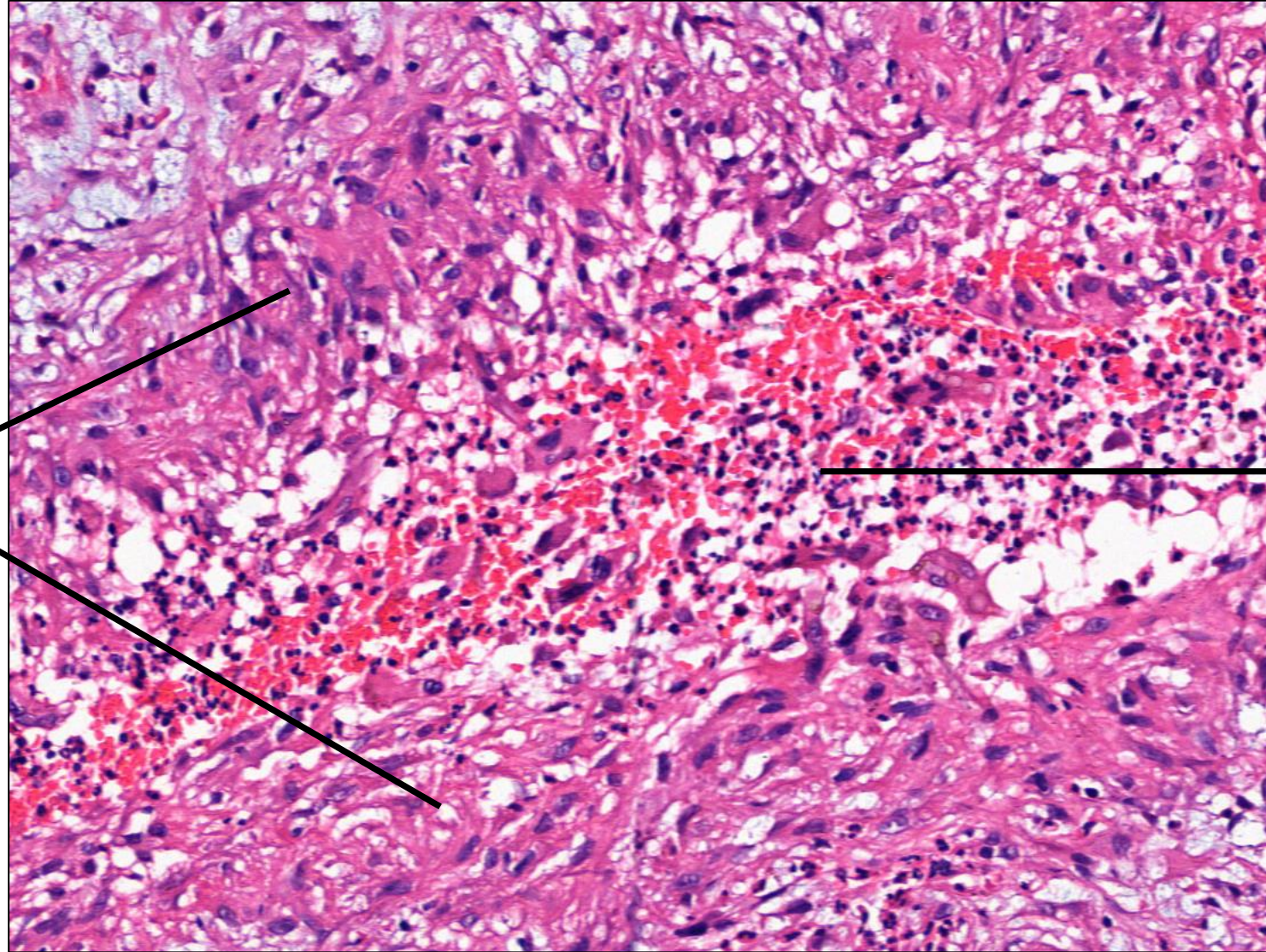
*Courtesy: Dr B V Rama Chandra, Prof & HOD, GIMSR,
Kanthi Skin Cosmetology Centre, Visakhapatnam*

Epidermis shows mild acanthosis with regular elongation of rete ridges



Inflammation is noted mainly in the deep dermis

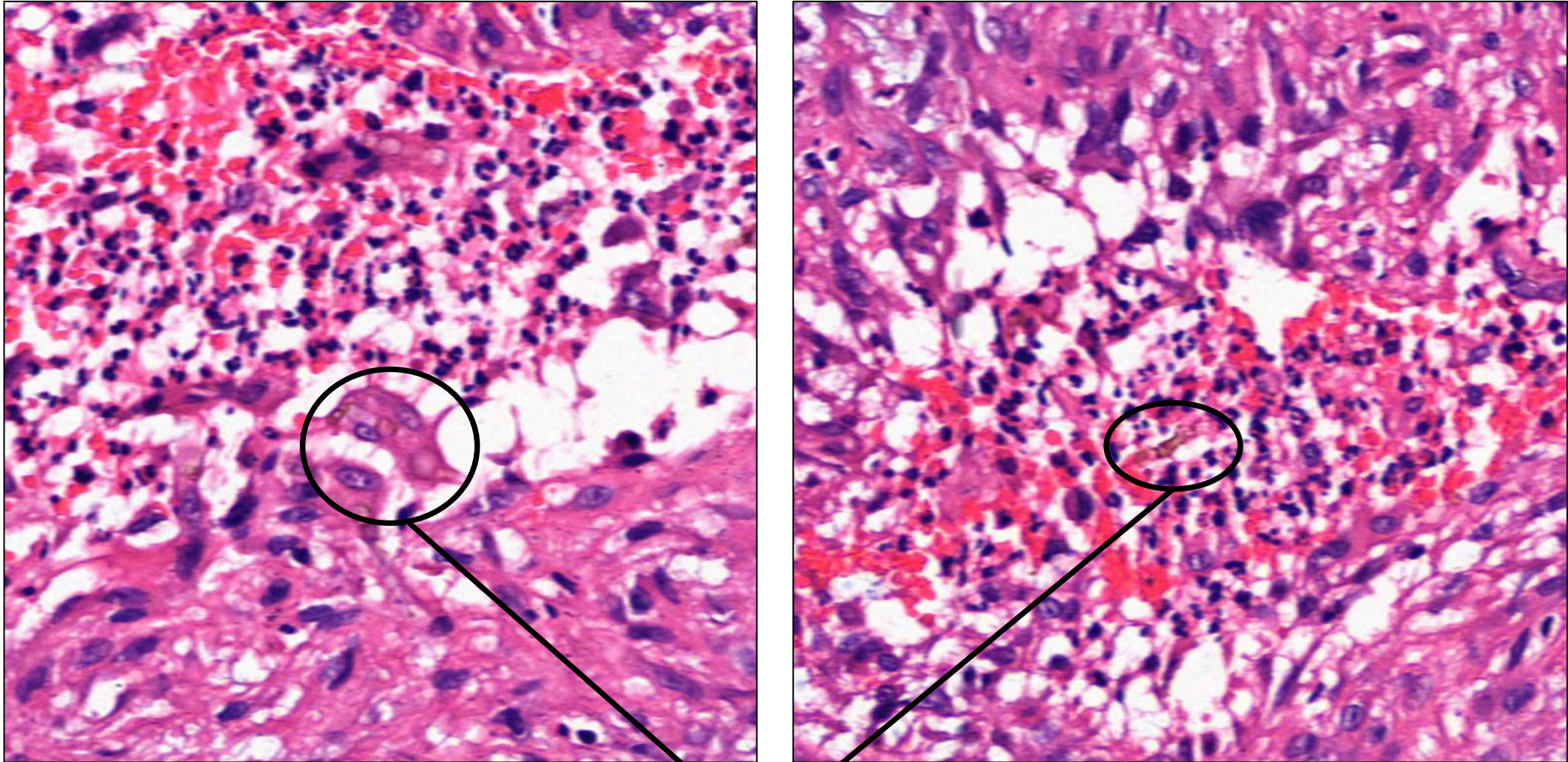
Suppurative granuloma



Epithelioid
histiocytes

Neutrophils

Diagnosis : Suppurative granuloma, Pheohyphomycosis



Pigmented fungal hyphae noted within the suppurative granulomas