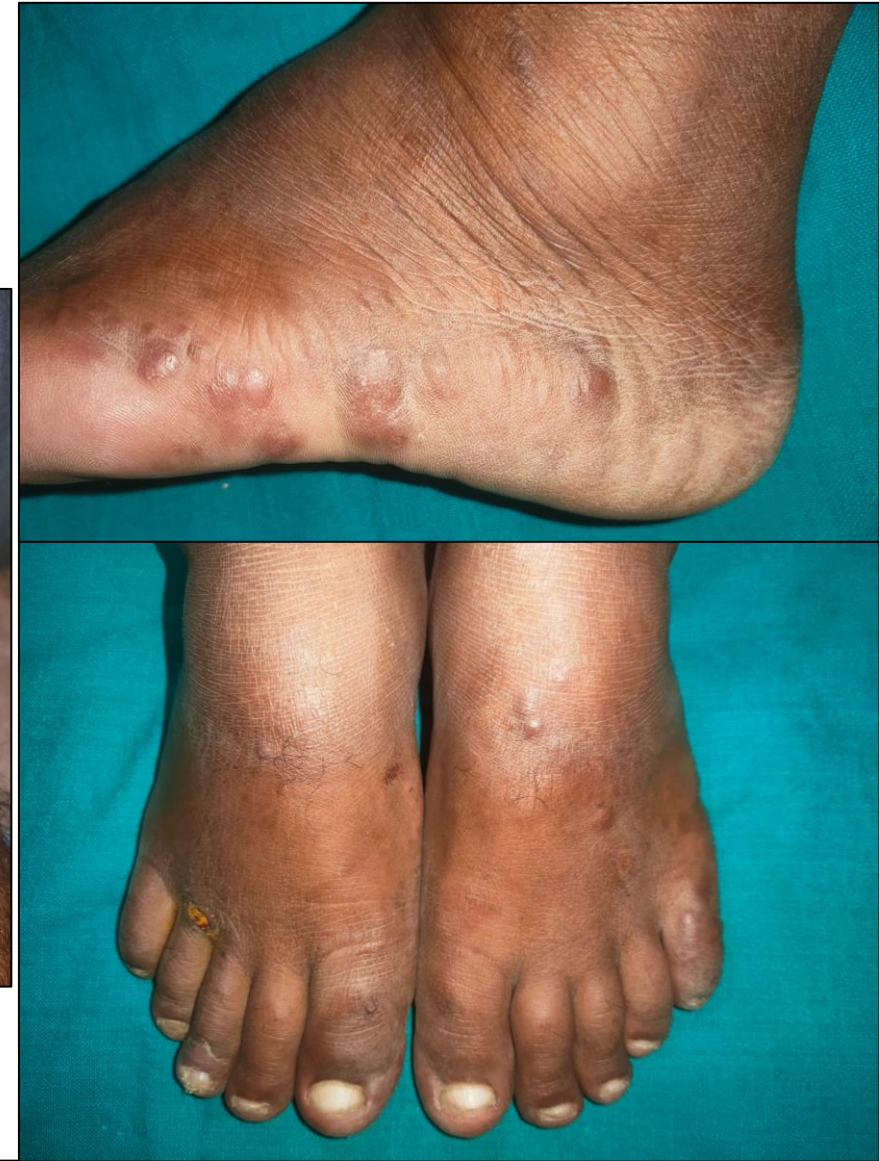
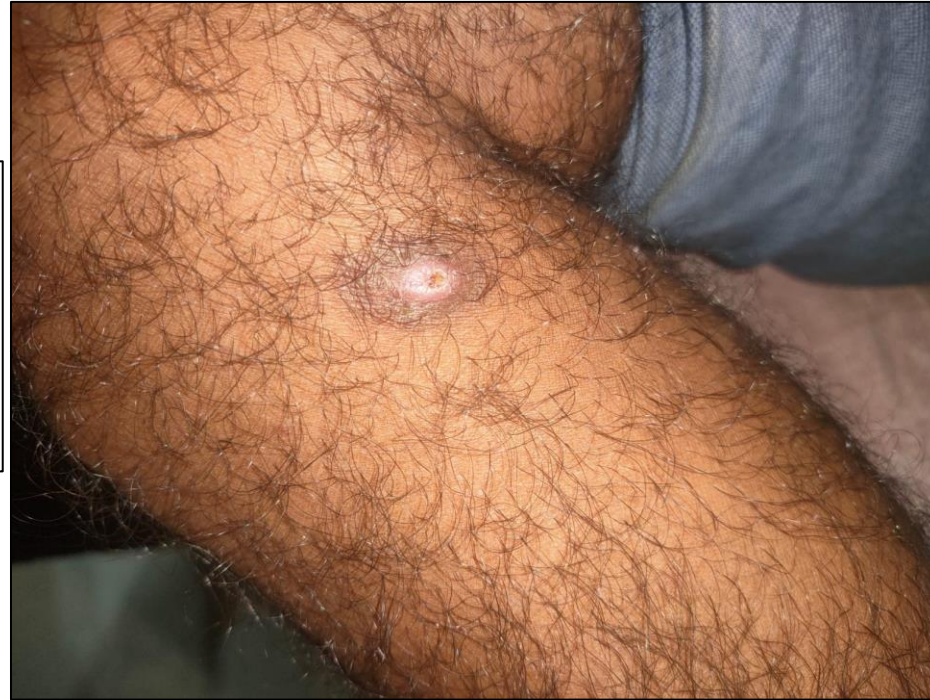
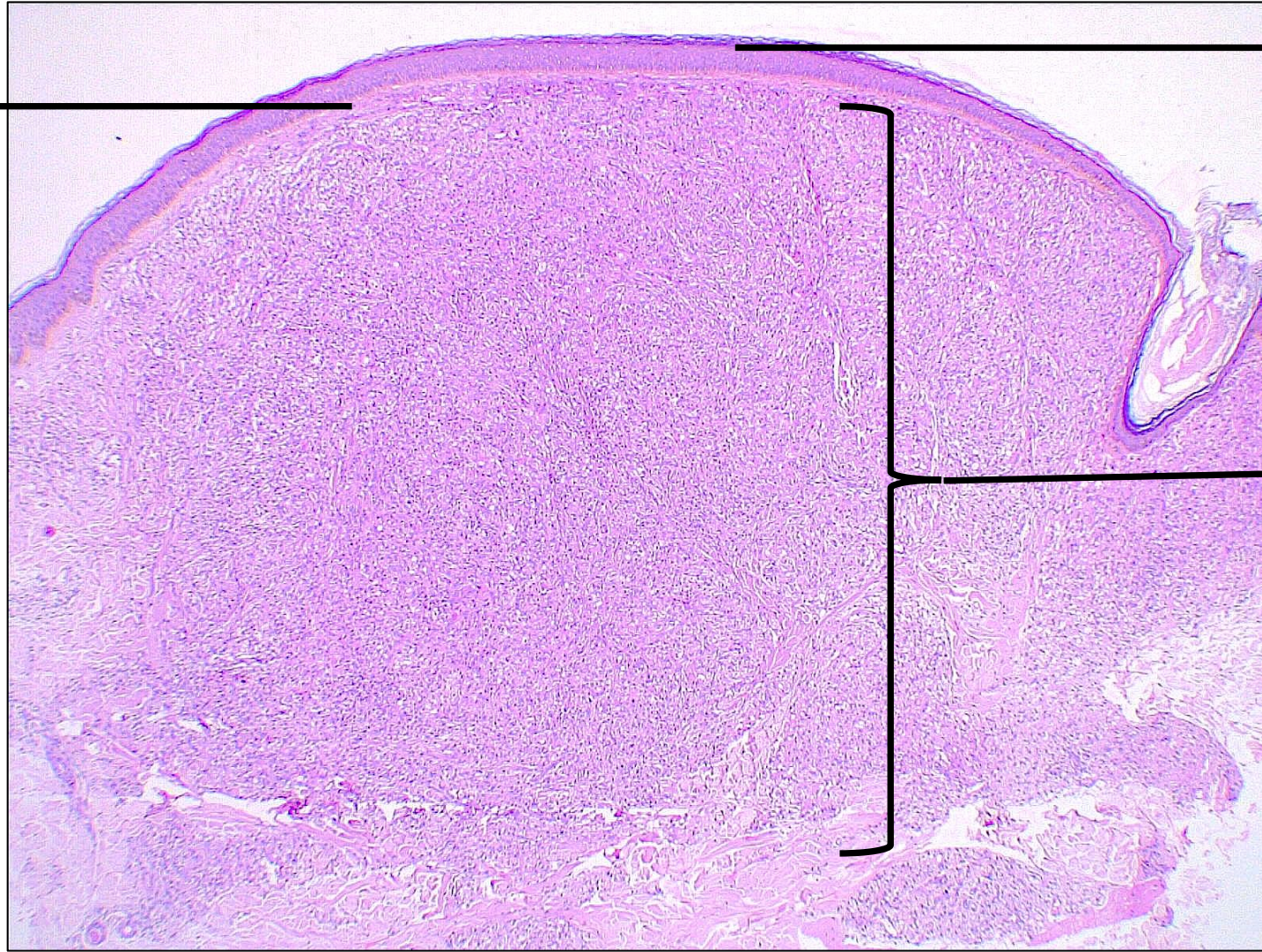
## DERMA PEARLS: DERMPATH PEARL - 8

25/M,  
Multiple skin coloured papules  
and nodules over buttocks, thighs  
and both hands.  
Peripheral nerves thickened.



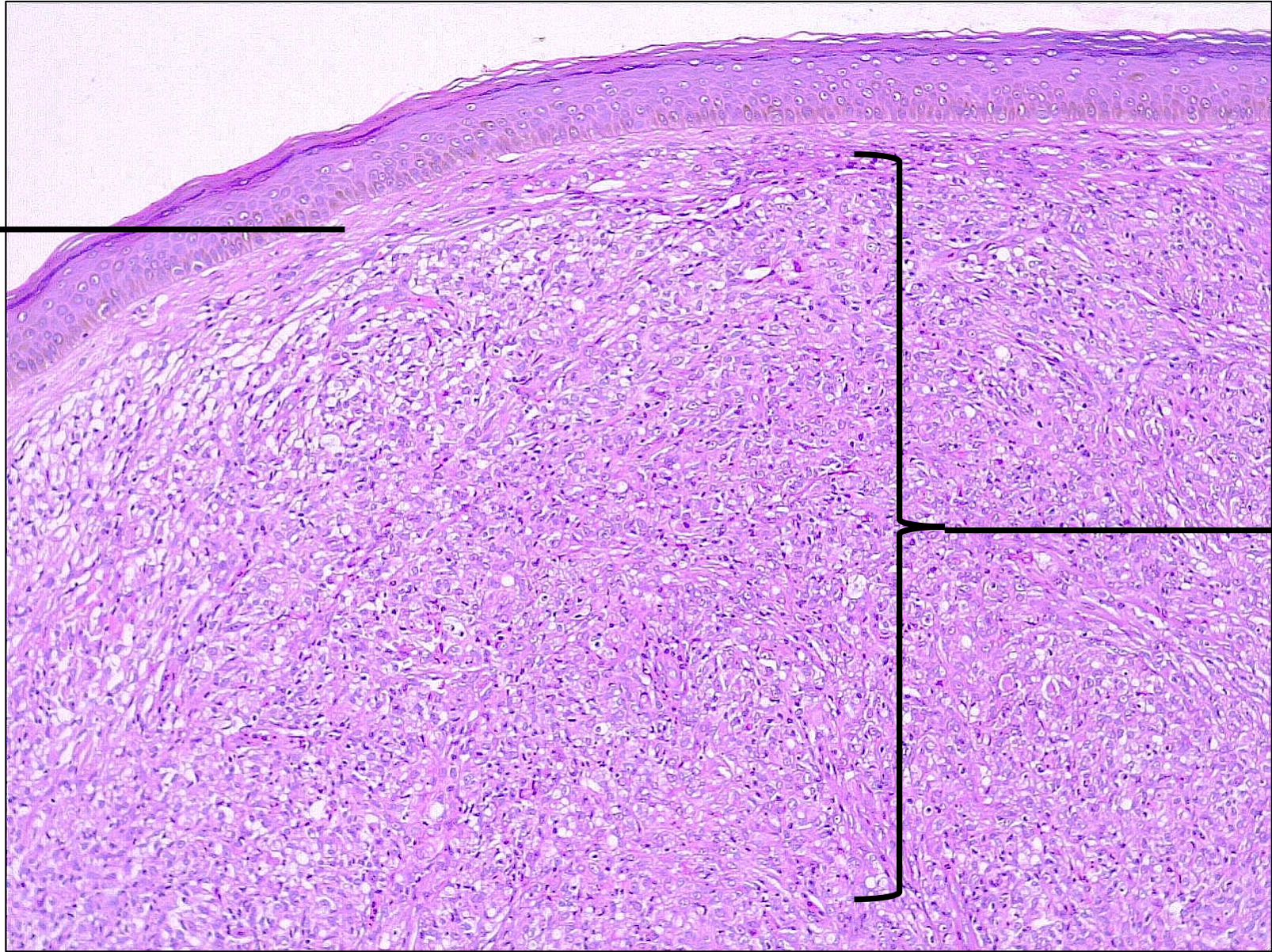
Courtesy: Dr T Narayana Rao, NR Skin & Cosmetology Centre,  
Prof & HOD, GVPIHCMT, Visakhapatnam

Grenz zone  
(Thin layer of  
uninvolved upper  
dermis)



Thin epidermis

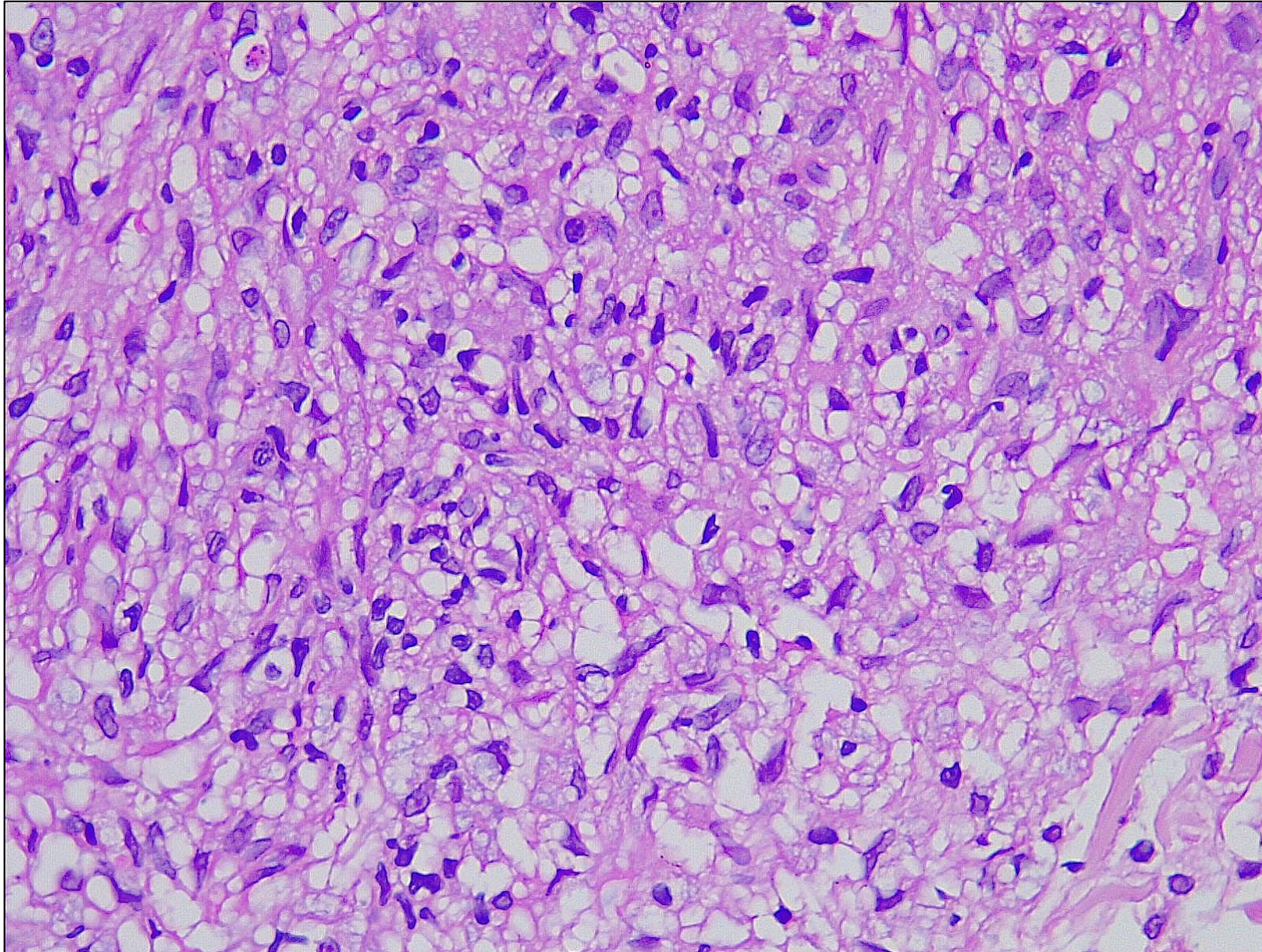
Superficial and deep  
dermis show diffuse  
inflammation



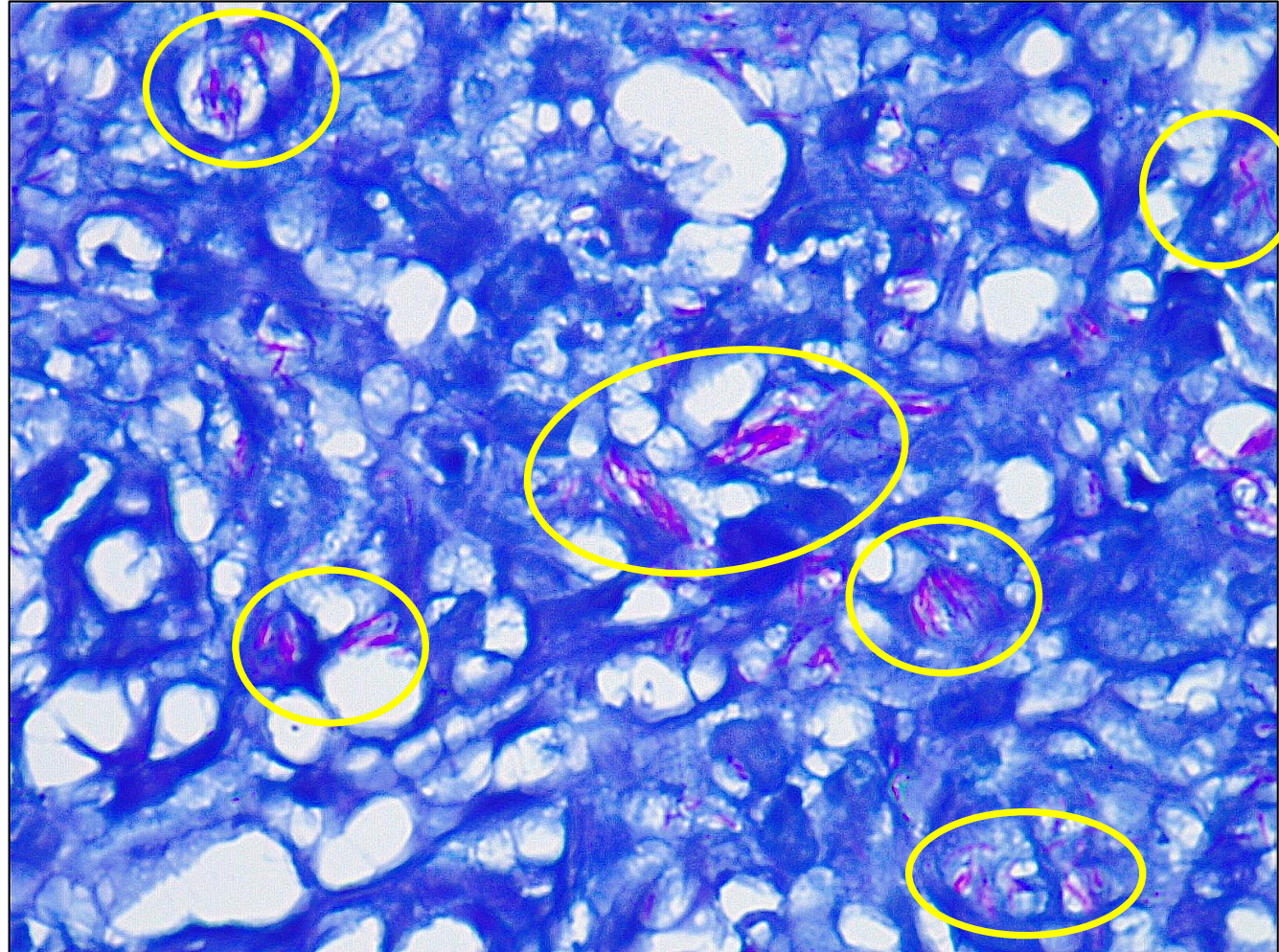
Grenz zone  
(Thin layer of  
uninvolved upper  
dermis)

Diffuse and dense  
infiltration with  
foamy macrophages

Diffuse and dense infiltration with foamy macrophages



# Diagnosis : Lepromatous leprosy



Fite-Faraco stain shows abundant lepra bacilli