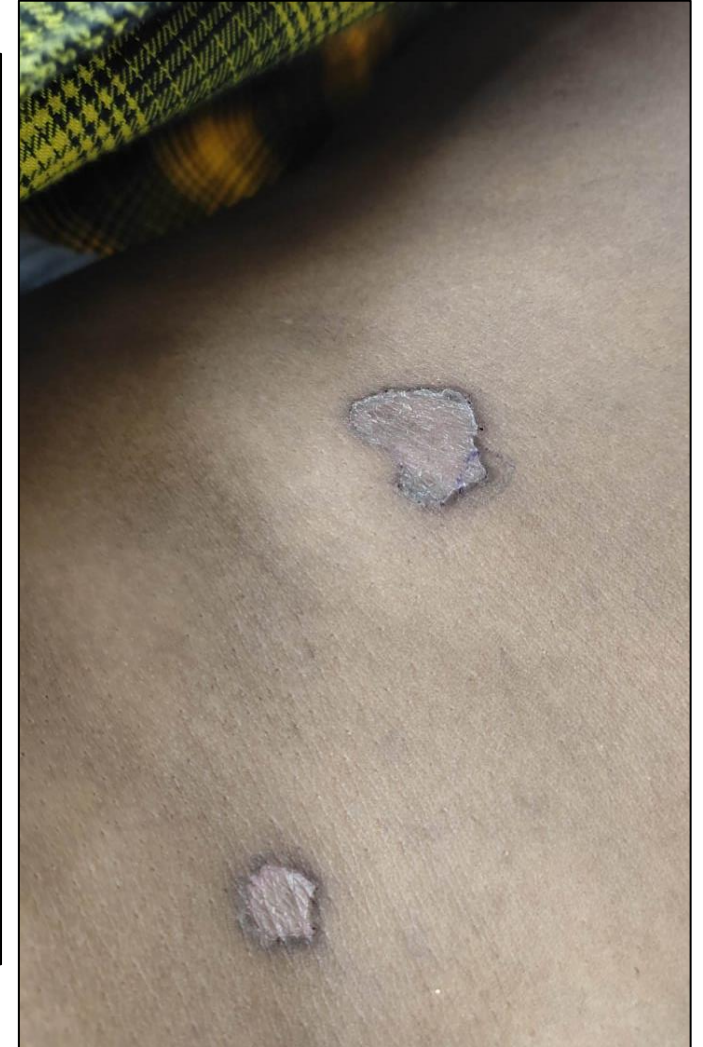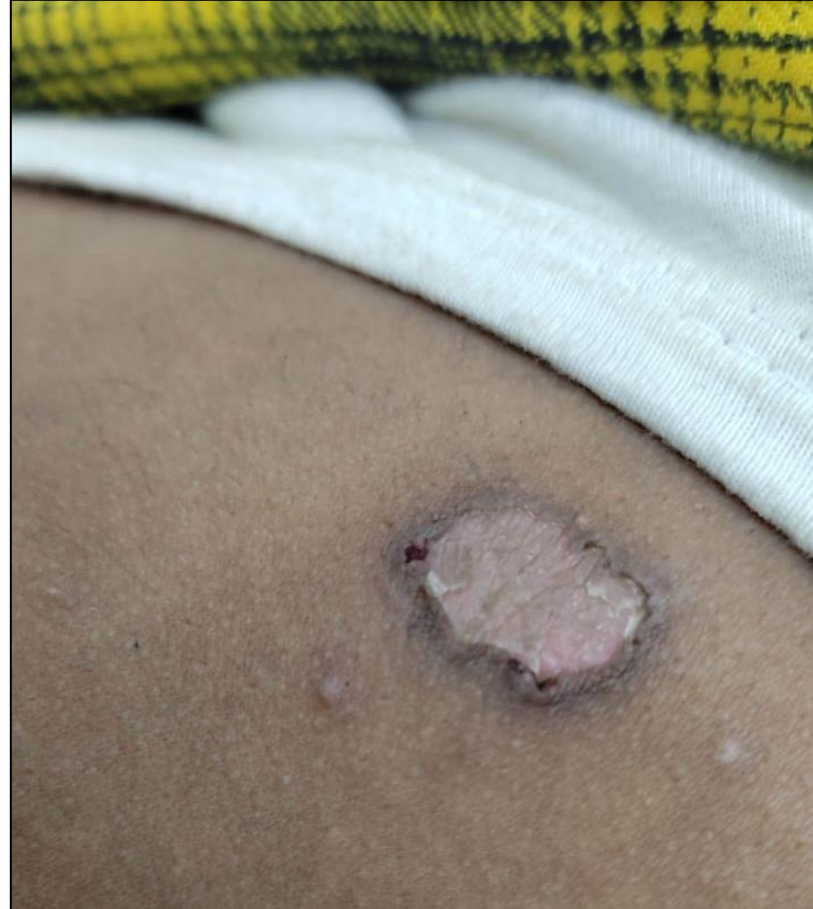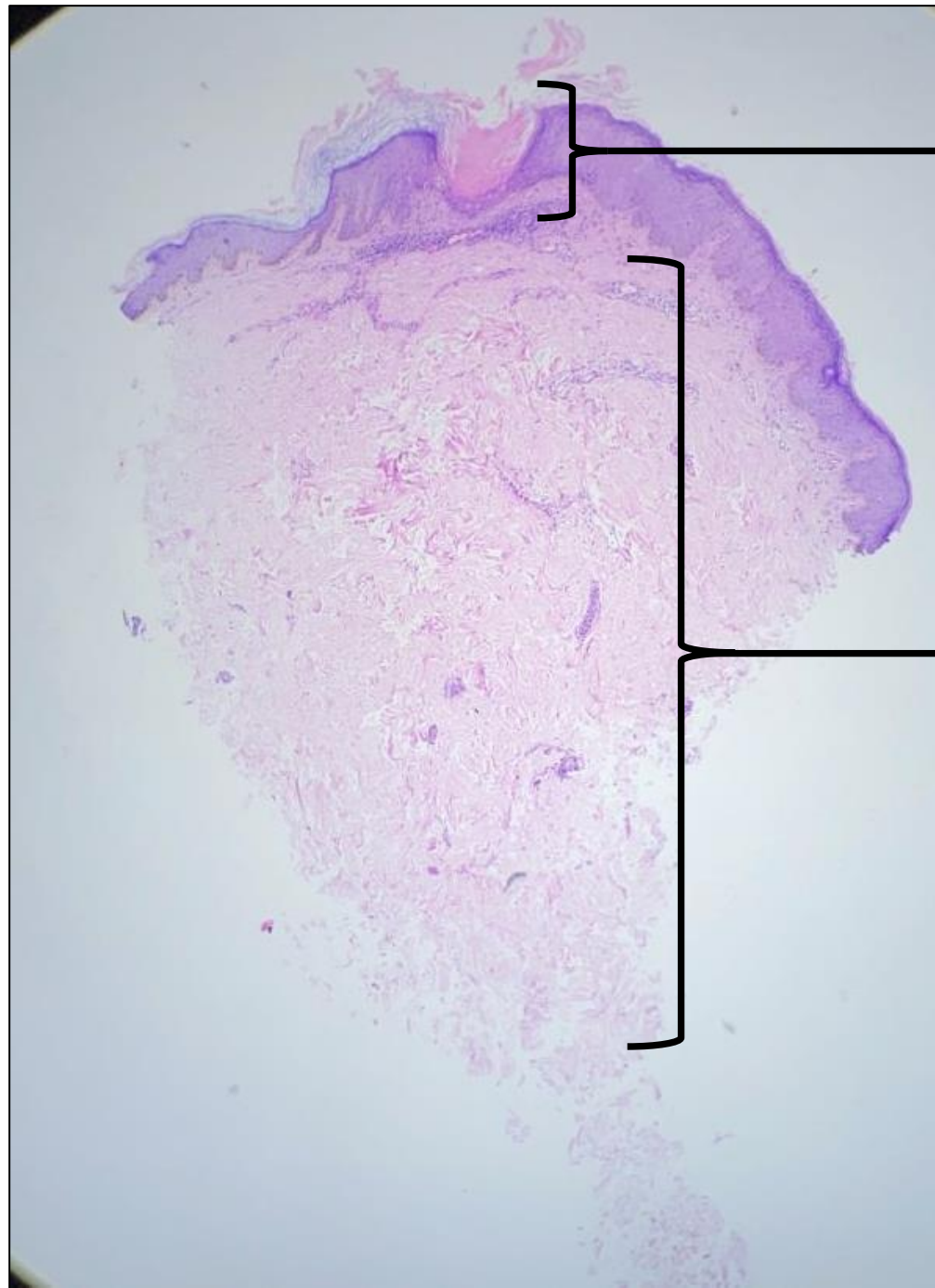


DERMA PEARLS: DERMPATH PEARL - 9

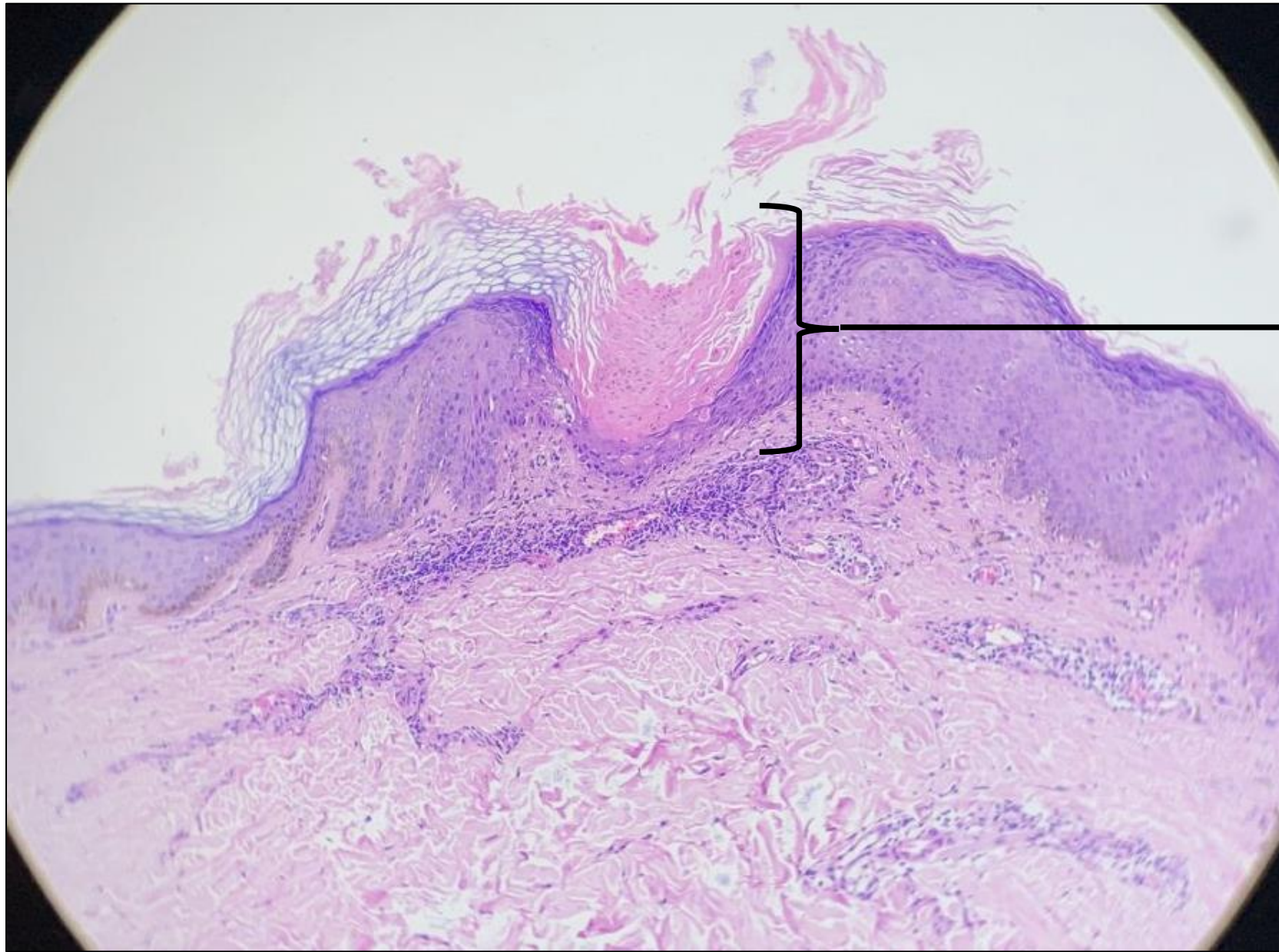
35/M,
Multiple, erythematous atrophic
plaques with well-defined
keratotic border and gutter-like
furrow over abdomen and back
for 10 yrs





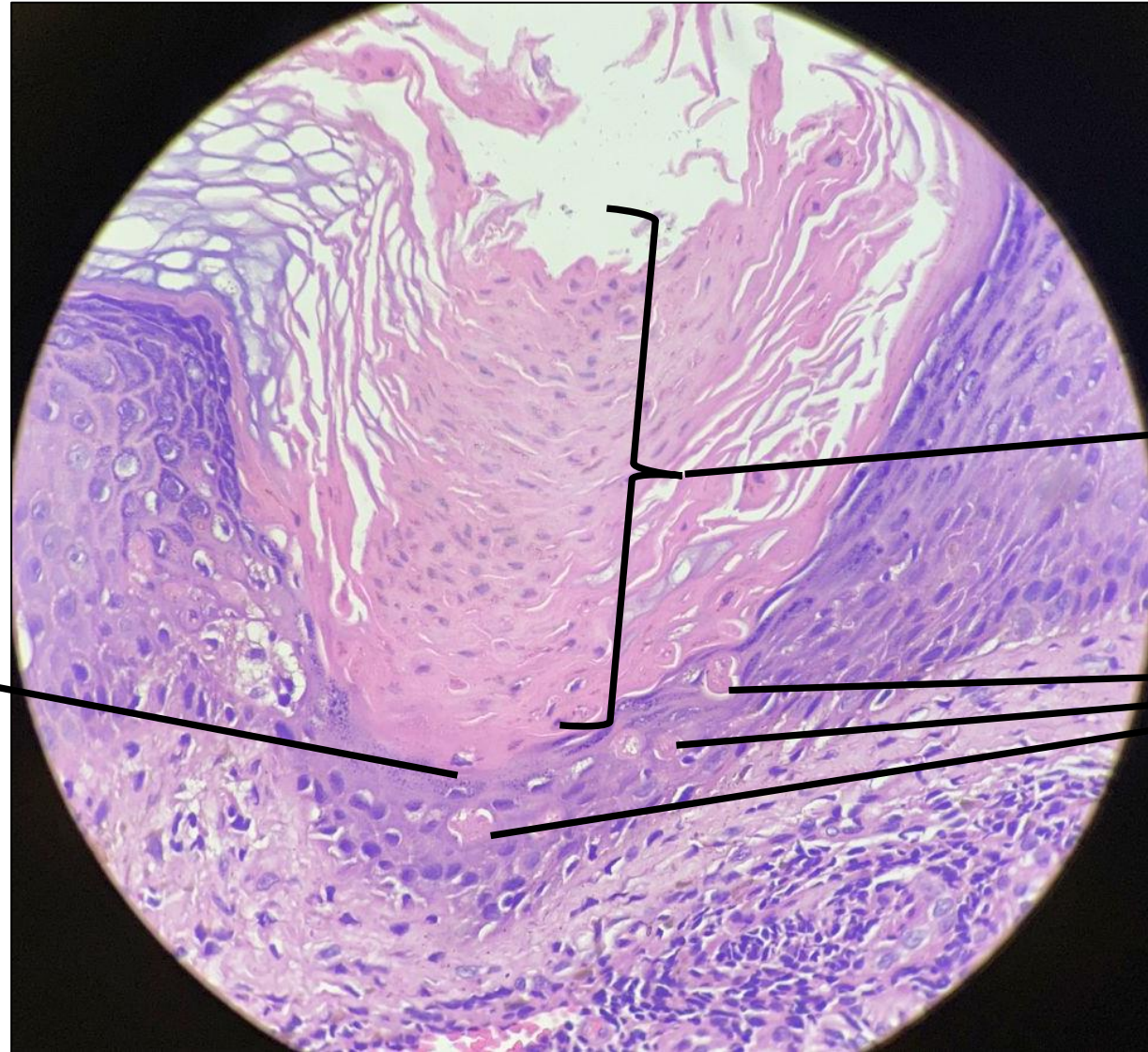Focal epidermal
invagination

The dermis appears
unremarkable



Within the epidermal invagination, there are tiers of parakeratotic columns

Diagnosis : Porokeratosis



Beneath the tiers of parakeratotic columns, granular layer is absent

Tiers of parakeratotic columns

Few dyskeratotic keratinocytes are also noted