



DERMA PEARLS: DERMOSCOPY-11

CICATRICAL ALOPECIA-4

FOLLICULITIS DECALVANS

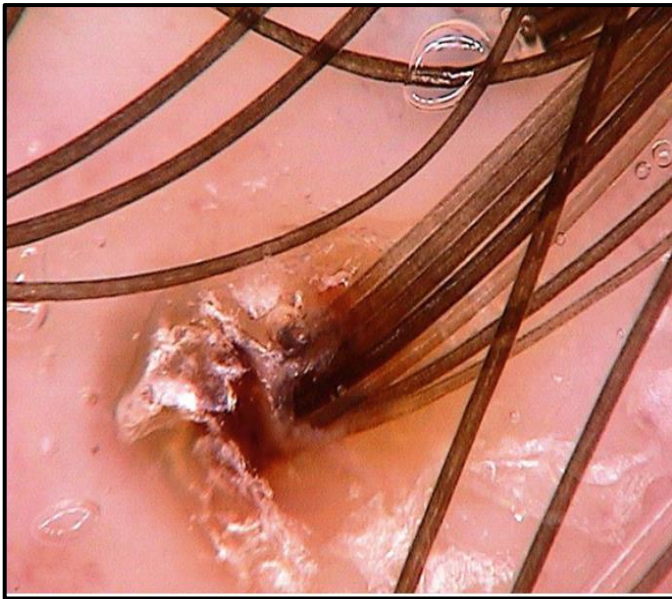
- Folliculitis decalvans is a neutrophilic primary cicatricial alopecia characterized by inflammatory perifollicular papules & pustules.
- It generally occurs in adult males, predominantly involving the vertex and occipital areas of the scalp.

Active disease

- Tufts of five or more hairs in one follicular unit
- Yellow follicular pustules
- Yellowish tubular scaling with collar formation
- Yellow discharge
- Starburst sign
- Folds of epidermal hyperplasia
- Vessels: elongated loops, coiled vessels, concentric perifollicular arrangement

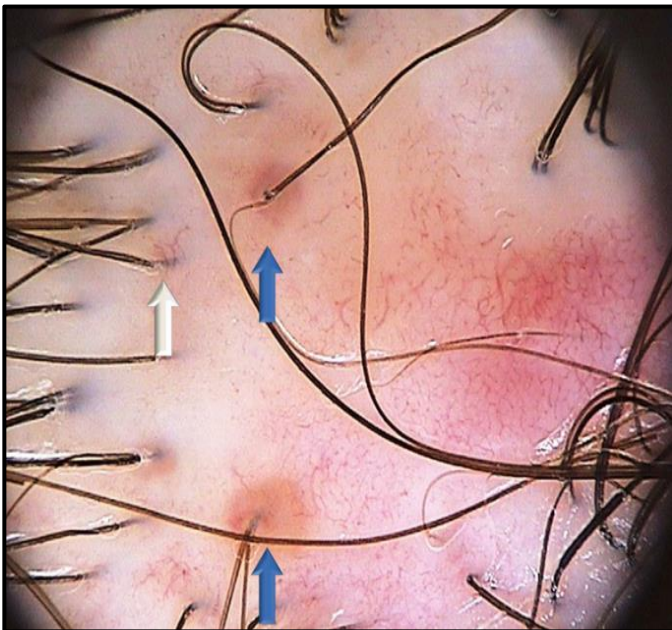
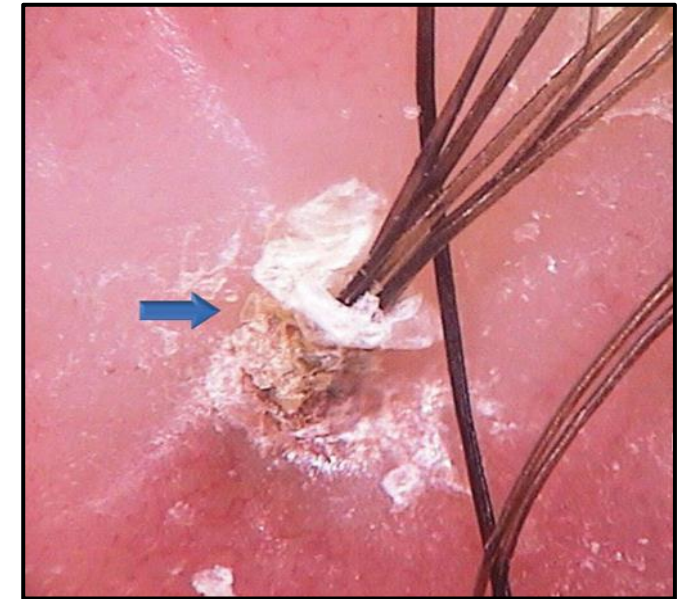
Late - stage , inactive disease

- Folds of epidermal hyperplasia
- Milky red areas lacking follicular openings
- White areas lacking follicular openings



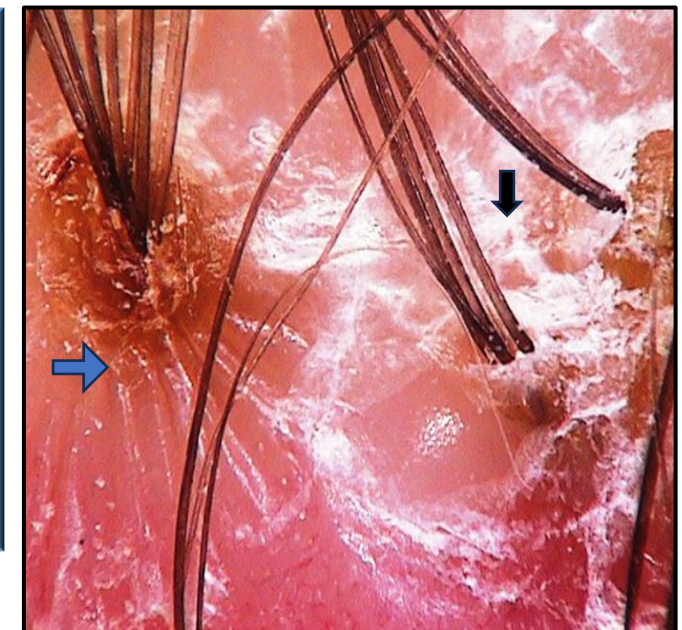
Tufted hairs:
several hairs (5 or more) emerge from one dilated follicular opening.

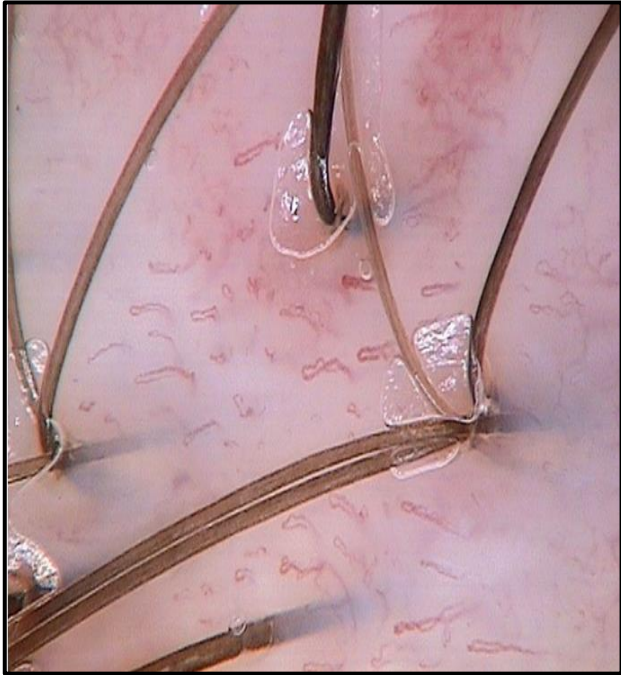Yellowish tubular scaling with collar formation:
tubular scaling with yellowish scales surrounding a tuft of 5 hairs. The scales roll away from the hairs and form a collar-like structure.



Follicular pustules:
Pustules (blue arrows) visible as yellow sharply demarcated areas around the follicular units. Elongated blood vessels (white arrow) around the follicular unit- pre-pustule stage

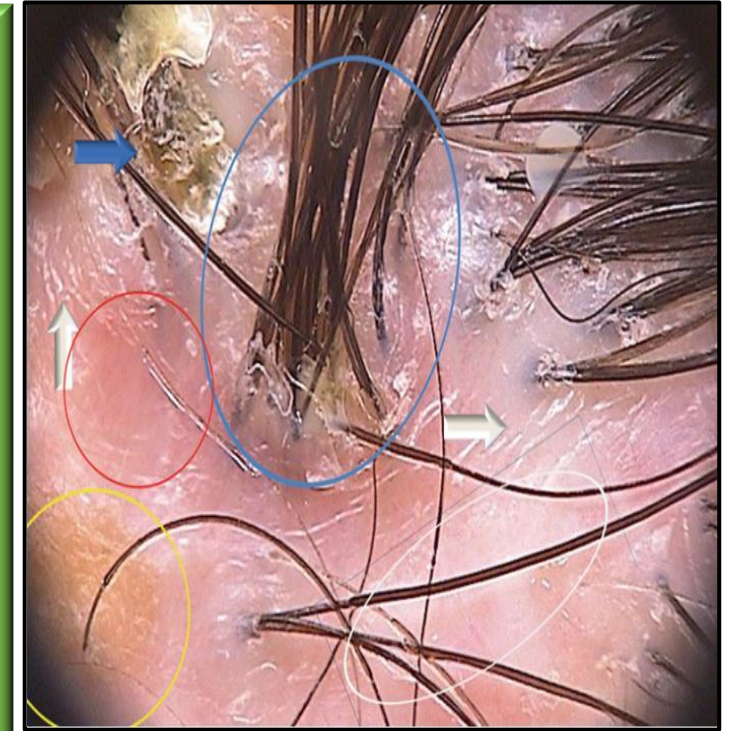
Starburst pattern hyperplasia:
Surrounding the follicular unit (blue arrow).
Irregular epidermal hyperplasia
(black arrow)





Vascular pattern:
several elongated looped and lace-like vessels.
Other abnormalities include coiled vessels and a perifollicular concentration of elongated vessels.

- **Blue ring:** Tufts of ≥ 5 hairs in one follicular unit
- **Yellow ring:** Yellow follicular pustules
- **Blue arrow:** yellowish tubular scaling with collar formation
- **Red ring:** milky red areas lacking follicular openings
- **White ring:** white areas lacking follicular openings
- **White arrows:** folds of epidermal hyperplasia



- Hallmark of folliculitis decalvans is development of scars & areas of follicular pustules.
- Presence of pustules could be marker of severity & activity.

Ref: Fabris MR, Melo CP, Melo DF. Folliculitis decalvans: the use of dermatoscopy as an auxiliary tool in clinical diagnosis. An Bras Dermatol. 2013;88(5):814-6. [Int J Trichology](#). 2017 Jul-Sep; 9(3): 140–141. Atlas of trichoscopy; L.Rudnicka et al

COMPILED BY
Dr.T.VANI
Dr.ASHWANI KOTYADA