



# DERMA PEARLS: DERMOSCOPY-12

## CICATRICAL ALOPECIA- 5 DISSECTING CELLULITIS OF SCALP

**Synonyms:** Dissecting folliculitis; Perifolliculitis capitis abscedens et suffodiens of Hoffman




- Dissecting cellulitis of scalp is a **neutrophilic primary cicatricial alopecia** characterized by perifollicular pustules, nodules and abscesses with interconnecting sinus tracts.
- It is a chronic, progressive, inflammatory disease that starts with occlusion of follicular openings on **scalp vertex** or **occiput**.

### Trichoscopic features of active dissecting cellulitis

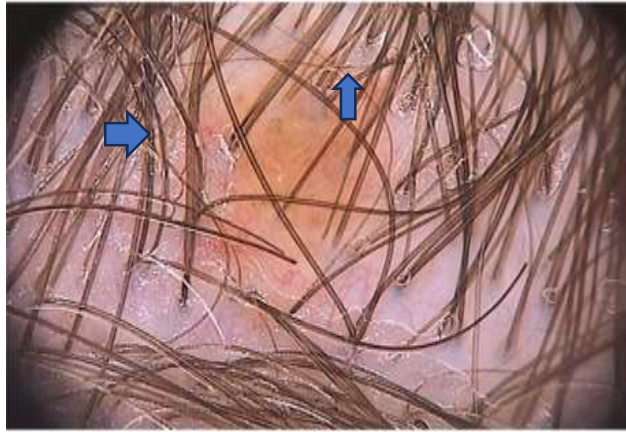
- Yellow structureless areas
- Yellow 3D (soap bubble) dots with or without hair shafts
- Black dots
- Pinpoint-like vessels with a whitish halo
- Cutaneous clefts with emerging hairs
- Hair tufts

### FOLLICULAR OCCLUSION OF TETRAD

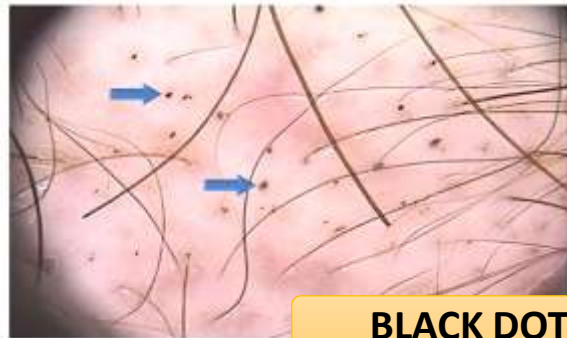- **Dissecting cellulitis**
- Hidradenitis suppurativa
  - Acne conglobata
  - Pilonidal sinus

CLINICAL IMAGES	TRICHOSCOPIC FEATURES	INFERENCE
<p><b>EARLY STAGE :</b></p> 	<p><b>EARLY STAGE :</b> Simulate alopecia areata</p> <ul style="list-style-type: none"> <li>• <b>Black dots</b></li> <li>• <b>Yellow dots</b></li> <li>• <b>Broken hairs</b></li> <li>• <b>Perifollicular pustule</b></li> </ul>	<ul style="list-style-type: none"> <li>• Weakened hair shafts broken at scalp level.</li> <li>• Follicle unable to start a new anagen phase and remains empty accumulating sebum and keratin.</li> <li>• Hair shafts broken at the same level</li> <li>• Active stage</li> </ul>
<p><b>ABSCEDENS STAGE:</b></p> 	<p><b>ABSCEDENS STAGE:</b></p> <ul style="list-style-type: none"> <li>• <b>Yellow structureless areas</b></li> <li>• <b>Yellow dots</b></li> <li>• <b>Polytrichia/ Hair tufts</b></li> </ul>	<ul style="list-style-type: none"> <li>• <b>LAKES OF PUS</b> around hair follicles.</li> <li>• Larger areas of Sebum accumulation and keratin in the follicular infundibulum.</li> <li>• Characteristic <b>3D SOAP BUBBLE APPEARANCE</b>.</li> <li>• Emergence of five or more shafts per follicular unit.</li> </ul>
<p><b>FIBROTIC STAGE:</b></p> 	<p><b>FIBROTIC STAGE:</b></p> <ul style="list-style-type: none"> <li>• <b>White areas</b></li> <li>• <b>Cutaneous clefts</b></li> </ul>	<ul style="list-style-type: none"> <li>• Lacking follicular openings and represents tissue fibrosis, clinically described as shiny patches of alopecia.</li> <li>• Hair shafts may emerge from such clefts organized into hair tufts with different sizes.</li> </ul>

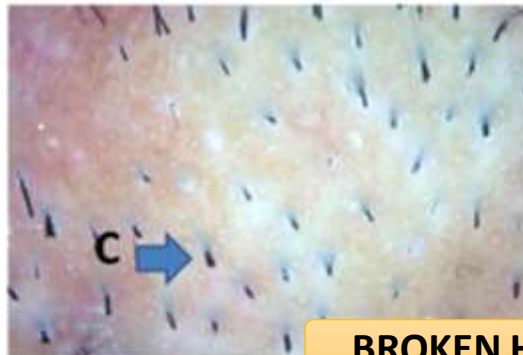
## EARLY STAGE



PERIFOLLICULAR PUSTULES

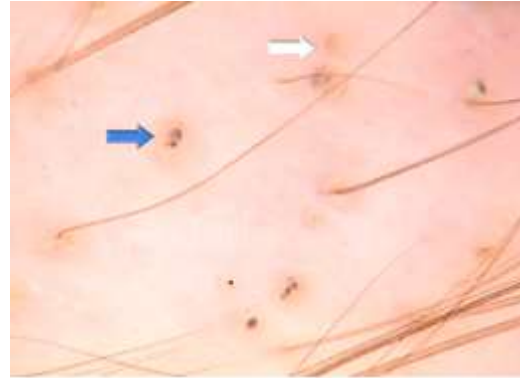


BLACK DOTS

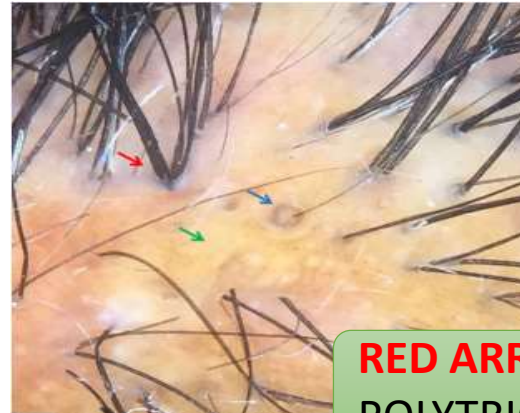

BROKEN HAIRS

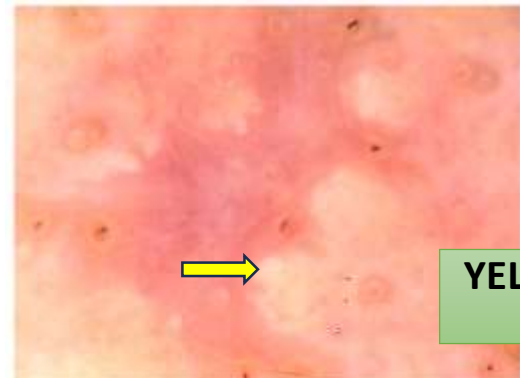
## ABSCEDENS STAGE



YELLOW (SOAP BUBBLE) DOTS

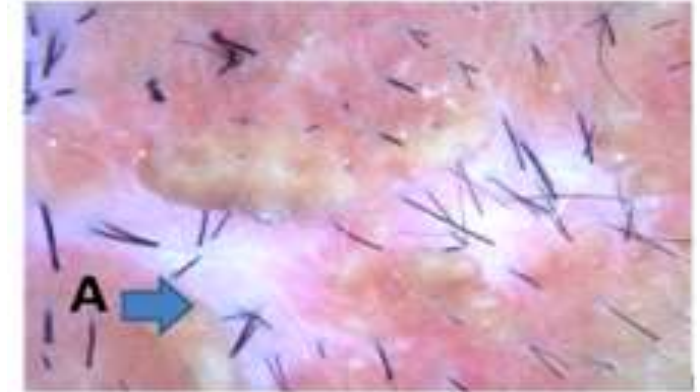


RED ARROW  
POLYTRICHIA

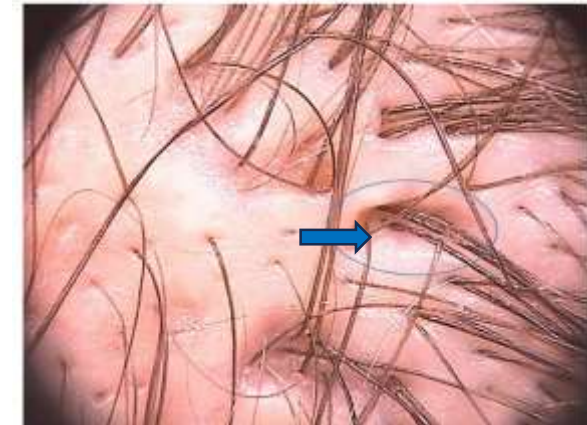

YELLOW STRUCTURELESS  
AREAS

## FIBROTIC STAGE



WHITE AREAS LACKING  
FOLLICULAR OPENINGS



CUTANEOUS CLEFTS WITH  
EMERGING HAIRS

Compiled by  
Dr.T.Vani  
Dr.G.Varthini Rithika  
Dr.SP.Swathiga