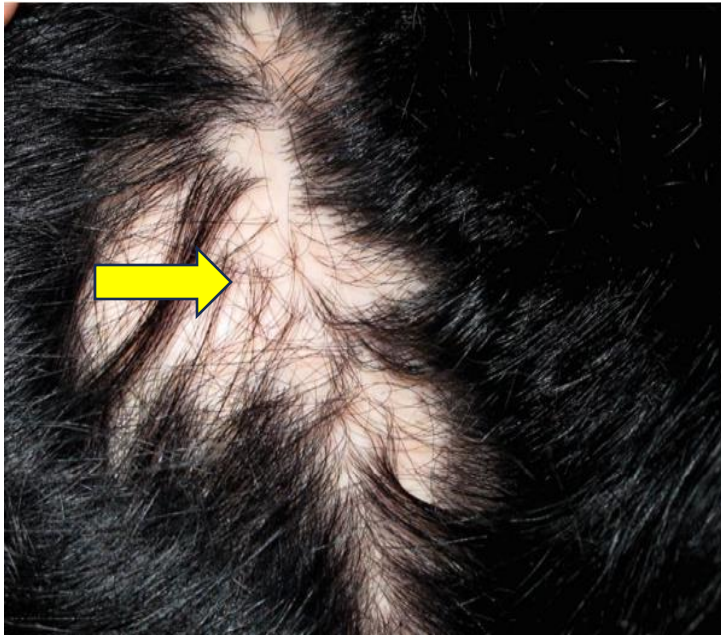




DERMA PEARLS: DERMOSCOPY-13

CICATRICIAL ALOPECIA-6

PSEUDOPELADE OF BROCCO

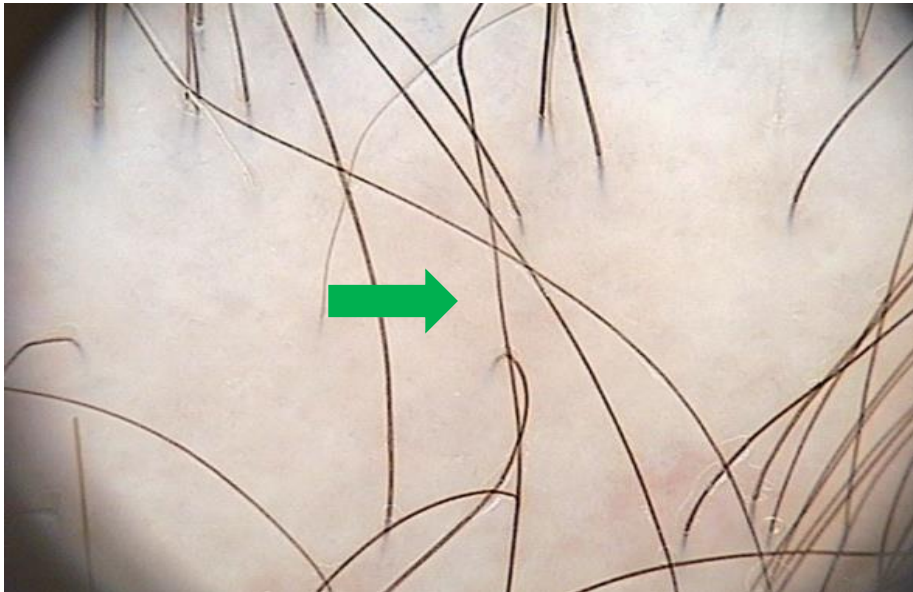


**FOOTPRINTS IN THE SNOW
APPEARANCE**

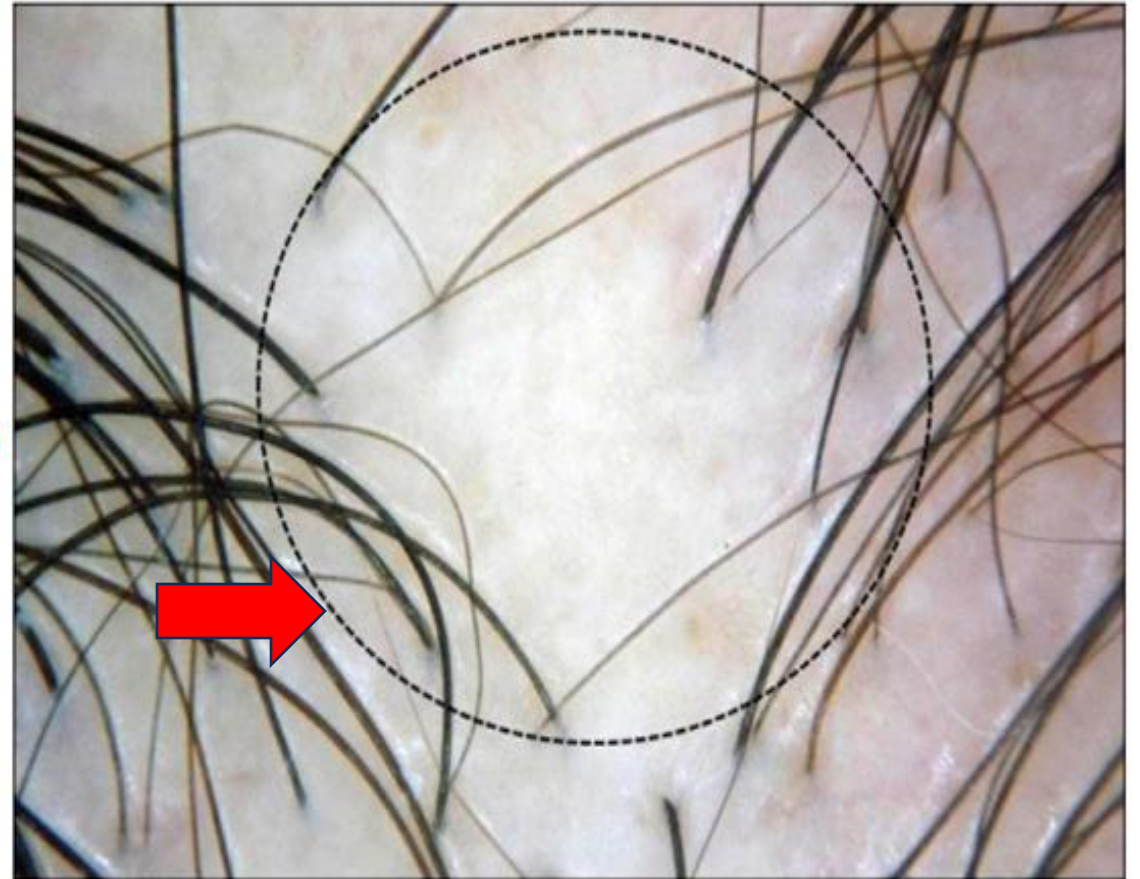
- ✓ Pseudopelade of Brocq is a lymphocytic primary **scarring** alopecia.
- ✓ Characterized by asymptomatic, **non inflamed white/porcelain white** small oval/round reticulate irregular patches in central scalp area which may imitate “**Footprints in the snow**” pattern.
- ✓ Clinically and dermoscopically, it is a diagnosis of exclusion as non-specific features are seen

TRICHOSCOPIC FEATURES

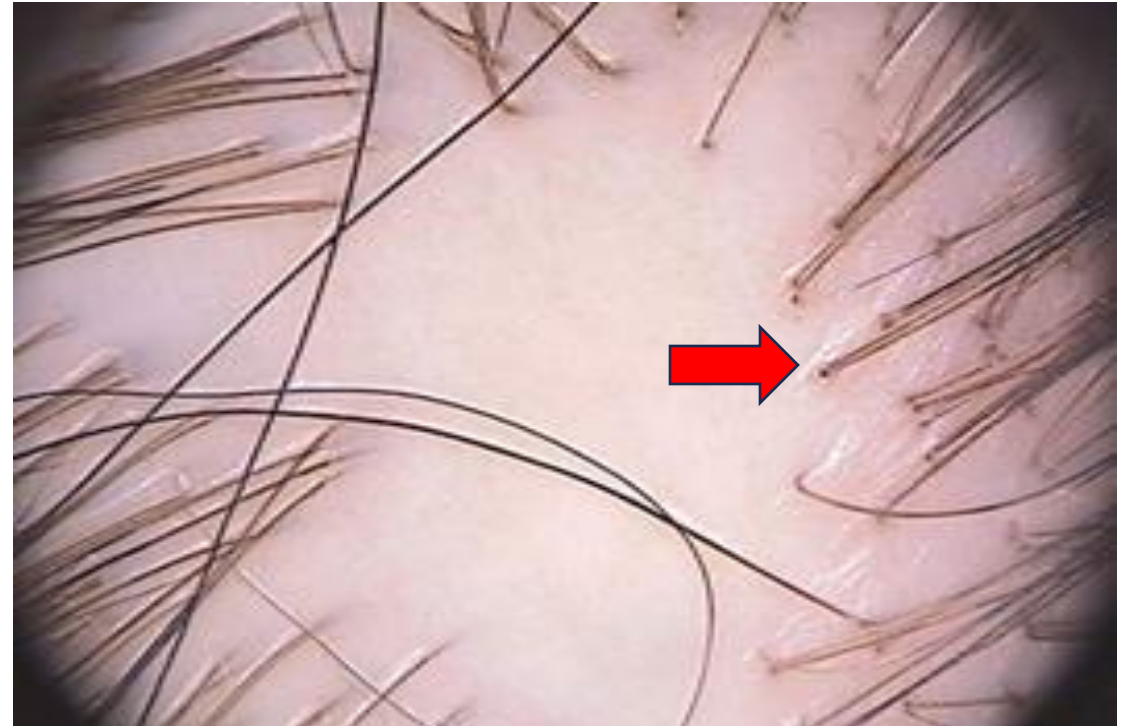
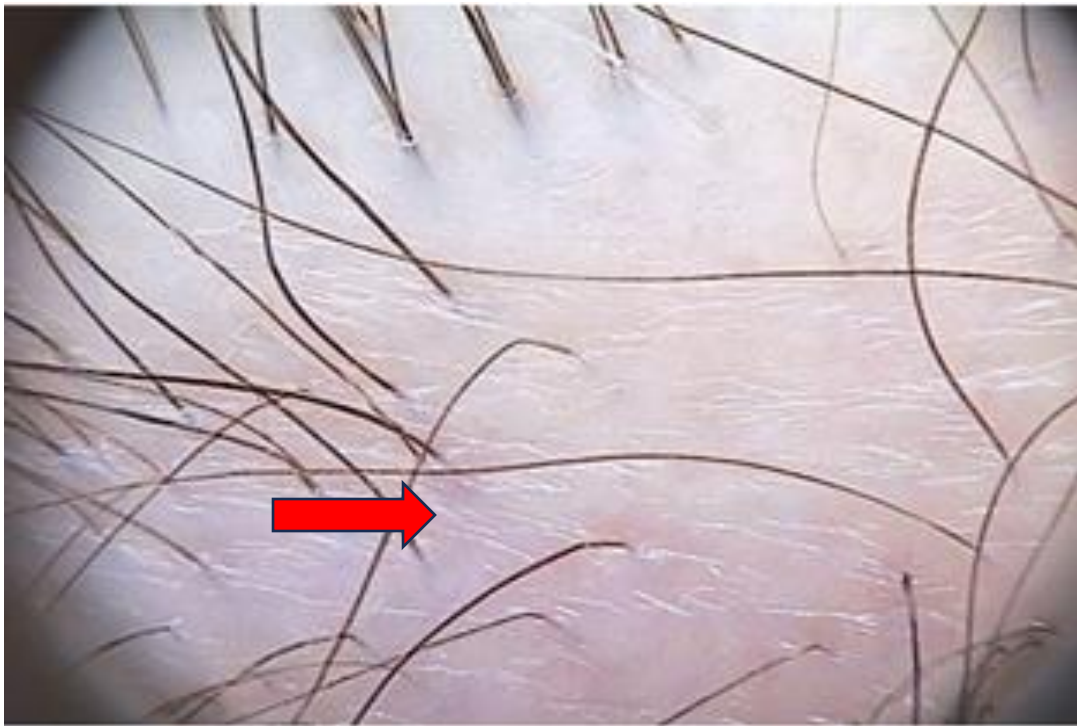
- No follicular openings
- White porcelain grey beige,erythematous and milky white areas
- Dystrophic hairs at the periphery of the lesion
- No features indicative of other types of cicatricial alopecia.



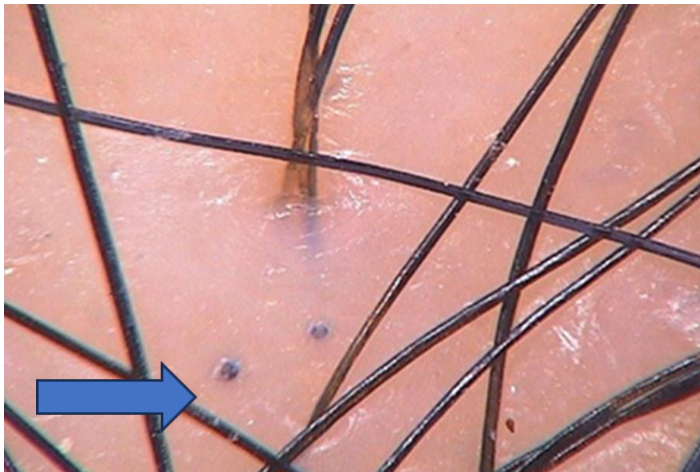
WHITE PORCELAIN,GREY BEIGE AREAS



BLACK CIRCLE: LACK OF FOLLICULAR OPENINGS



FINE PARALLEL FOLDS: INDICATES CICATRICAL ALOPECIA



BLACK DOTS : Correspond to Hair residues

Ref: Atlas of trichoscopy, L. Rudhnika et al
Dermanetnz. Dr Ahmed Sadek, Cairo Hospital for Dermatology
& Venereology (Al-Haud Al-Marsoud), Egypt. March 2022.

Compiled by
Dr.T.VANI
Dr.MAMTA
Dr. PRATHYUSHA