

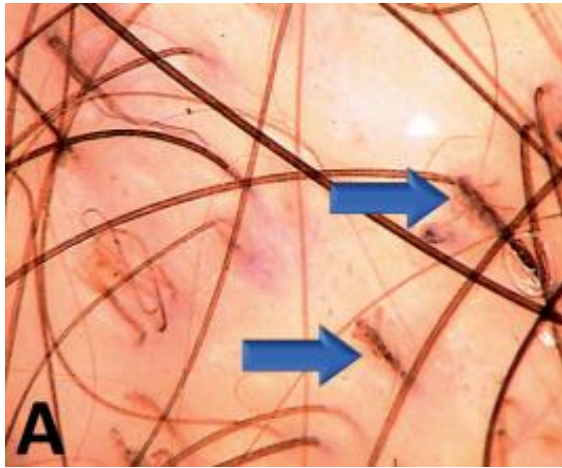


# DERMA PEARLS: DERMOSCOPY-4

## NON CICATRICAL ALOPECIA- 2 TRICHOTILLOMANIA

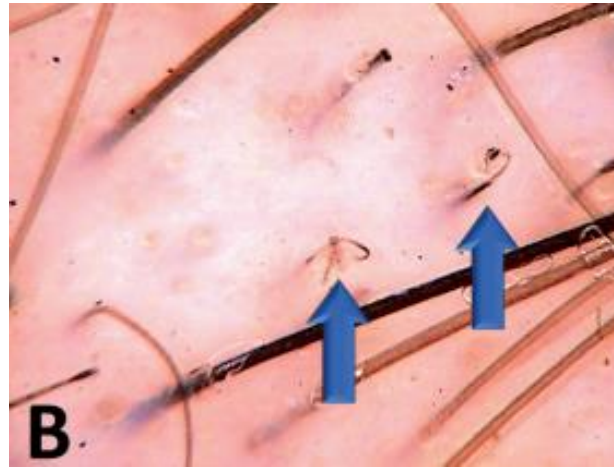
| Trichoscopic feature             | Description  |
|----------------------------------|--|
| Broken hairs at different levels | Numerous hairs broken in different levels among normal terminal hairs  |
| Short vellus hair                | Pale, non-medullated thin and short hairs                              |
| Black dots                       | Broken hair at the level of scalp                                      |
| Trichoptilosis                   | Split ends commonly observed in very short hairs                       |
| V hair                           | Two or more hairs broken at the same length emerging from one follicle |
| Hair powder                      | Almost entirely damaged hair shaft which shows only sprinkled dots     |
| Yellow dots                      | Empty follicular openings filled with keratotic material and sebum     |
| Mace hair                        | Broken terminal hairs with a bulging distal end                        |

| Trichoscopic feature  | Description   |
|-----------------------|---|
| Coiled hair           | Irregular coil shaped hairs resulting from pulling force  |
| Exclamation mark hair | Hairs with a thin-pale proximal end and a thick-darker distal end   |
| Follicle haemorrhages | Blood spots associated with forced plucking   |
| Branched hair         | A hair shaft with obliquely detached pieces   |
| Angulated lines       | Fractured hairs forming a sharp angle along the hair shaft  |
| Flame hair            | Thin, wavy shaped hair residues   |
| Tulip hair            | Short hairs with a slightly thinner proximal end than the distal end and tulip-like hyperpigmentation pattern at the distal end |
| Concentric hair       | A broken hair presenting as a central black dot surrounded with a black circle  |
| Burnt matchstick sign | Bulbous dark proximal end with a linear stem  |



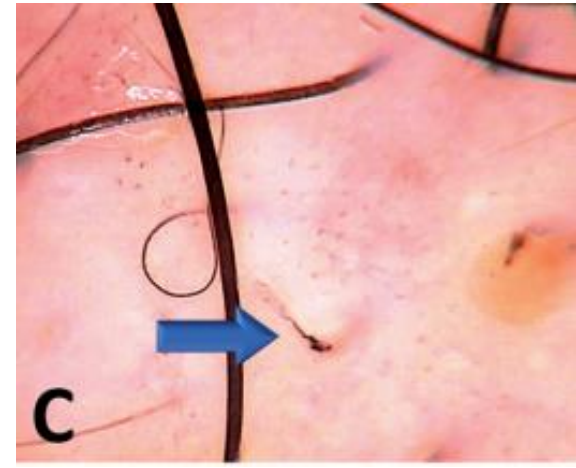
**A**

**A- broken hairs at different levels**



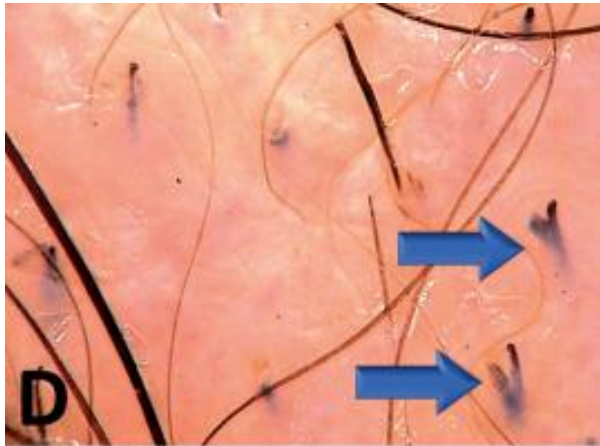
**B**

**B- coiled hairs**



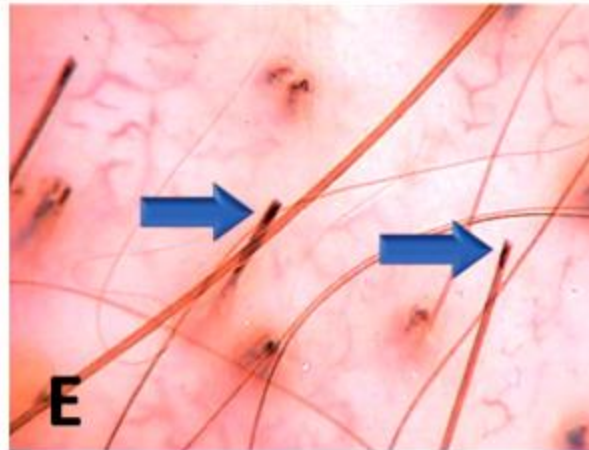
**C**

**C- Flame hair**



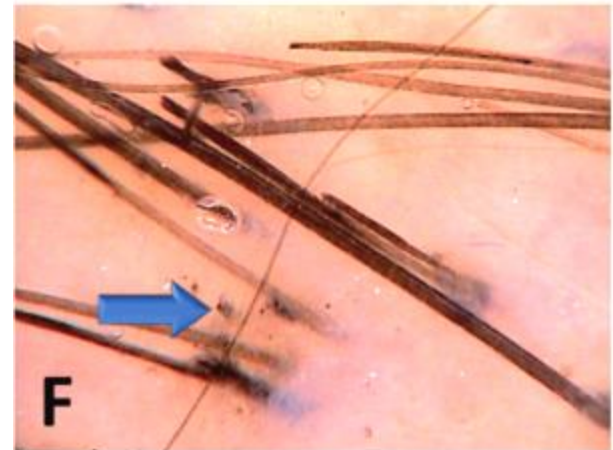
**D**

**D- V hair**



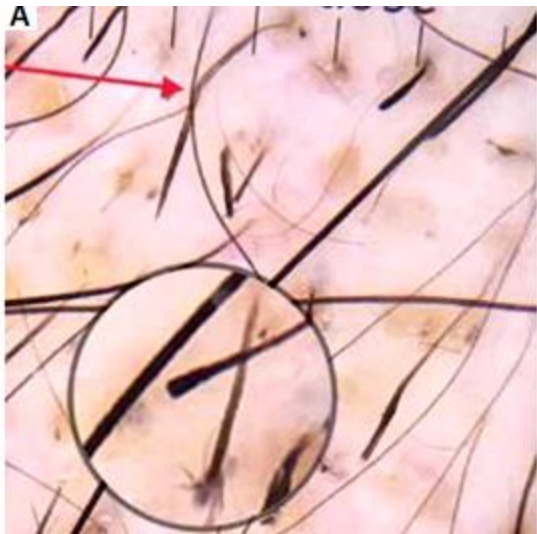
**E**

**E- Tulip hair**

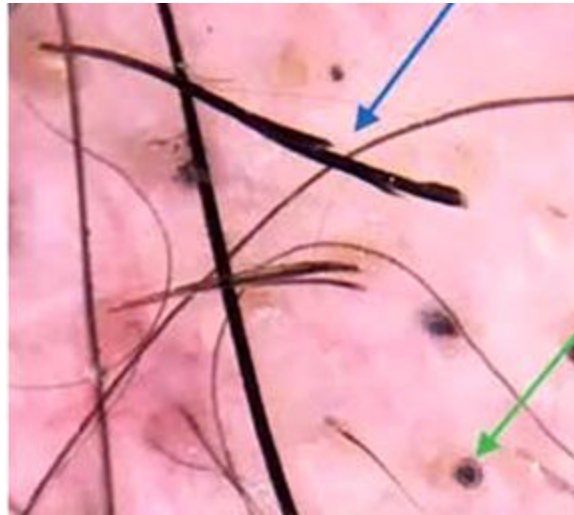


**F**

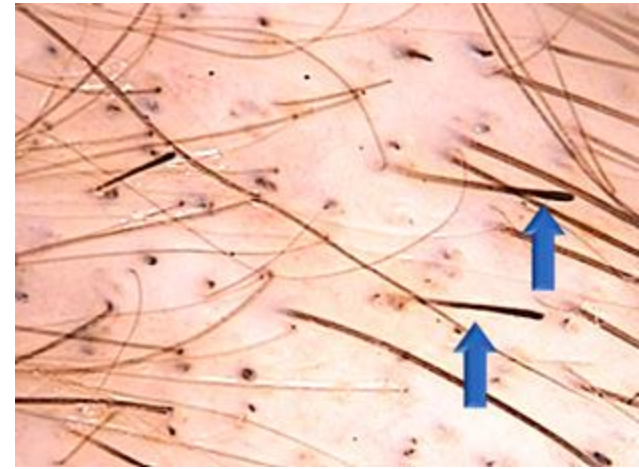
**F- Hair powder**



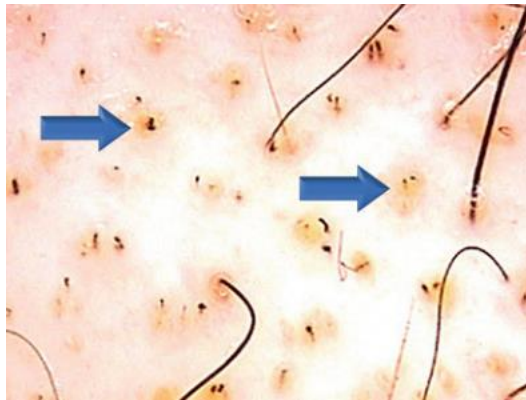
**Angulated hair (red arrow)**  
**Trichoptilosis (circle)**  
**Mace hair (circle)**




**Branched hair (blue arrow)**  
**Concentric hair (green arrow)**



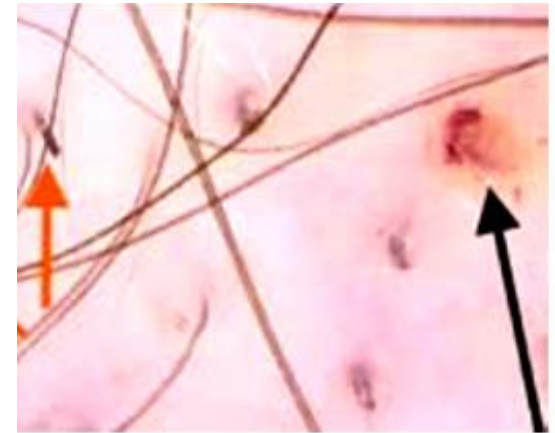
**Exclamation mark hairs**



**Black dots in**  
**Yellow dots**



**Burnt matchstick sign (red arrow)**



**Broken hairs (orange arrow),**  
**Follicular haemorrhage (black arrow)**

**Compiled by**  
**Dr.T.Vani**  
**Dr.SP.Swathiga**